

## Severe Paediatric Epilepsy Syndromes

Colin D Ferrie

Leeds General Infirmary, Leeds

Figures used here have been modified with permission from: "A Clinical Guide to Epileptic Syndromes and their Treatment" Second edition. London, Springer (courtesy of CP Panayiotopoulos)

### Introduction

Most children who develop epileptic seizure disorders do well. 60-70% can expect to eventually become seizure free. This chapter concerns those who do not. It deals with those epilepsies which can reasonably be predicted to follow a severe course, rather than with those which are usually relatively mild but which can, on occasions, prove more difficult.

The term 'severe paediatric epilepsy syndrome' does not have a precise meaning. Other terms with which it overlaps include:

- Refractory
- Drug resistant
- Malignant

In the ILAE's 2001 Diagnostic Scheme, the term 'epileptic encephalopathy' was introduced and defined as:

*"A condition in which the epileptiform abnormalities themselves are believed to contribute to the progressive disturbance in cerebral function"*

Most of the conditions discussed here are epileptic encephalopathies. Hence they are characterised not only with resistant epileptic seizures, but also with an expectation that children with them will develop other problems, including learning difficulties, behavioural problems (including autistic behaviours) and sometimes physical problems such as ataxia. The concept implies that if epileptic activity can be controlled, these other problems will be minimised. Some of the disorders discussed, such as Ohtahara and Dravet syndromes, always behave as epileptic encephalopathies. Others, such as West and Lennox Gastaut syndromes usually do, whilst others, such as Doose syndrome, often do but quite frequently do not.

The epileptic encephalopathies are not neurodegenerative disorders in the usual meaning of that term. Therefore, we will not be considering conditions such as the cerebral lipofuscinoses ('Batten Disease').

### What makes an epilepsy severe?

We do not know the answer to this question. Almost certainly it has something to do with aetiology. Until recently, 'idiopathic' was often equated with 'mild' or 'benign' and 'symptomatic' with 'severe'. Also it was felt likely that epilepsies caused by ion channel disorders would be relatively mild. It is now clear that these are huge oversimplifications. Doose syndrome is considered an idiopathic generalised epilepsy but it often acts as an epileptic encephalopathy. Children with congenital hemiplegia due to middle cerebral artery infarcts may develop a severe epilepsy but more usually the epilepsy is mild. Dravet syndrome (one of the most severe of all childhood severe epilepsies) is a channelopathy.

## **Severe Epilepsy Syndromes of the Neonatal Period**

There are two well described epileptic encephalopathies in this age group. They share some common features.

### *Ohtahara syndrome (also known as Early Infantile Epileptic Encephalopathy)*

This is a rare epilepsy syndrome usually presenting in the first few days or weeks of life, but sometimes as late as 3 months of age. Clinically it is characterised by the occurrence of tonic seizures which can be generalised and symmetrical or lateralised. These tend to be very frequent (often hundreds a day), occur both during awake and sleep and can be single or occur in clusters (similar to infantile spasms). Other seizure types include focal motor seizures and hemi or generalised tonic-clonic seizures. Myoclonic seizures are not characteristic. The EEG shows a burst-suppression pattern both during awake and sleep (Fig. 1). Bursts, usually lasting 2-6 seconds, consist of high amplitude slow waves intermixed with spikes. These alternate with periods of suppression, usually lasting for 3-5 seconds, during which the EEG is flat or nearly flat. Tonic seizures can occur during the bursts or can be associated with periods of desynchronisation or 'accentuation' of the burst-suppression pattern.

Ohtahara syndrome is commonly caused by severe cerebral malformations, such as hemimegalencephaly, diffuse migrational disorders, porencephaly, Aicardi syndrome, etc. The prognosis is very poor. Half of infants affected are said to die within weeks or months of its onset. The remainder are left with severe learning difficulties and often with motor impairments (cerebral palsy). Survivors often show an evolution to West syndrome and this may subsequently evolve to Lennox-Gastaut syndrome. This observation led to the concept of the age-related encephalopathies.

Treatment with AEDs is usually ineffective. ACTH has been used, usually without effect.

### *Early Myoclonic Encephalopathy*

This is also a rare neonatal epilepsy syndrome often presenting very shortly after birth and nearly always within the first few weeks of life. It is characterised by erratic or fragmentary myoclonus consisting of myoclonias affecting the face and limbs which shift from one part of the body in a random and asynchronous manner. They may be single or repetitive and are usually very frequent, if not near continuous. Massive axial myoclonic jerks may also occur. Other seizure types seen include: focal seizures, often subtle and manifested with, for example, eye deviations or autonomic symptoms; tonic seizures; and epileptic spasms (usually later in the evolution of the disorder). The EEG shows a burst-suppression pattern (Fig.1), often more apparent in sleep than when awake. The myoclonias do not usually have an EEG correlate.

Early myoclonic encephalopathy is often caused by inborn errors of metabolism, such as amino and organic acidurias, disorders of purine metabolism and peroxisomal disorders. Detailed metabolic studies are mandatory. These should include CSF studies for hyperglycinaemia. Not surprisingly autosomal recessive inheritance is often apparent. Structural brain defects, except for the development of diffuse atrophy, are not expected. Unless a treatable metabolic disorder is found no effective treatment exists. There is a very high mortality in the early weeks and months of life and survivors are left with severe physical and mental impairments.

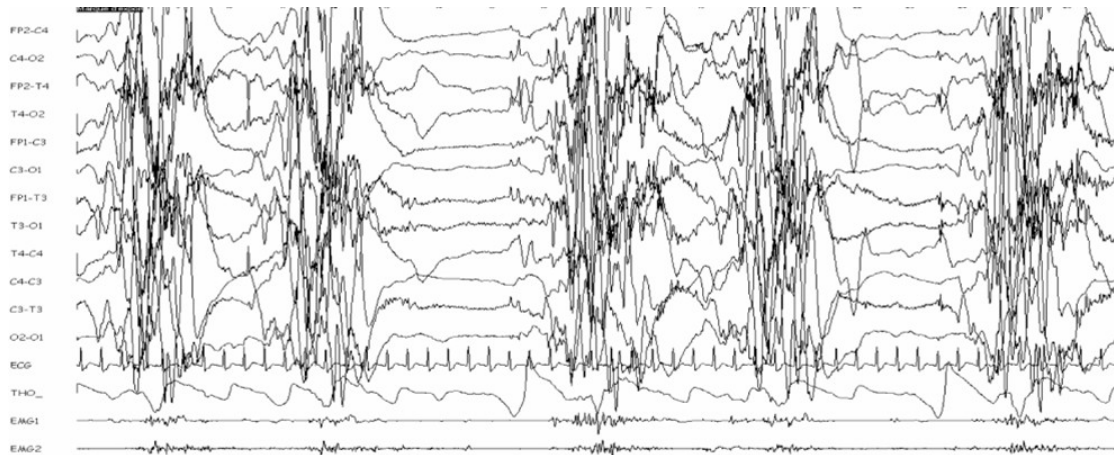


Figure 1. Burst-suppression (15mm /sec). This example is from a 15 day old infant with early myoclonic encephalopathy

### **Severe Epilepsy Syndromes of Infancy**

In infancy (i.e. the period from 1 month to 2 years of age) the first epilepsy syndrome described - West syndrome - occurs along with one of the most recently recognised epileptic encephalopathies - Dravet syndrome. Even more recently a third syndrome - migrating focal epilepsy of infancy - has been described.

#### West Syndrome

West syndrome comprises a triad of epileptic spasms, mental retardation and hypsarrhythmia. It usually starts between 3 and 12 months of age, with a peak at 5 months. Its incidence is 3-5 per 10,000 and is more common in boys.

The defining seizure type is epileptic spasms. This term is now preferred to infantile spasms, recognising the fact that the seizure type can occur in older children. They consist of sudden, brief contractions of axial and limb muscles lasting longer than myoclonic seizures (i.e. longer than 100 milliseconds) and shorter than tonic seizures (i.e. shorter than a second - although many would say shorter than 2 seconds). Characteristically they occur in clusters which may include tens or even hundreds of individual spasms. Spasms may be flexor, extensor or mixed flexor-extensor. The type does not appear to be important in terms of aetiology or prognosis. They are usually symmetrical. However, asymmetrical spasms do occur and often indicate focal structural brain pathology. Indeed a cluster of spasms may be preceded by or be followed by a focal seizure. Spasms usually occur on arousal or when alert. Exceptionally they occur during sleep. Loud noises, tactile stimuli and feeding may all precipitate spasms. Early on in the course of the condition spasms may be very subtle and infrequent (sometimes manifested with head nods), but tend to build up both in intensity and frequency such that they eventually become obvious.

Prior to the onset of spasms, development may have been normal or delayed, reflecting the underlying aetiology. Where development has been normal parents, often first notice a period of social disengagement, particularly for visual stimuli. Developmental deterioration during the period of active spasms is usual, but not universal. Most children who have had spasms will eventually have severe learning difficulties, but up to 15% will show normal or near normal development.

Hypsarrhythmia is the EEG pattern most commonly seen in children with West syndrome (Figure 2). However, up to a third have other patterns. It comprises a chaotic mix of asynchronous high amplitude slow waves with intermixed sharp waves and spikes. So-called atypical or modified hypsarrhythmia includes cases with asymmetries, persistent foci, some preservation of background rhythms and a degree of synchrony. Some of these, particularly the first two are associated with structural brain problems. During non REM sleep a degree of synchronisation is common and there may be preserved sleep elements. The EEG is usually normal in REM sleep. Particularly early on the disorder, the awake EEG may be normal whilst the sleep EEG is abnormal. The ictal EEG, that is the EEG associated with spasms is very variable, with at least 11 patterns being described. However, most commonly it shows a brief period consisting of a generalised high voltage slow wave, episodic, low amplitude fast activity and then attenuation or flattening of the EEG (electrodecremental response).

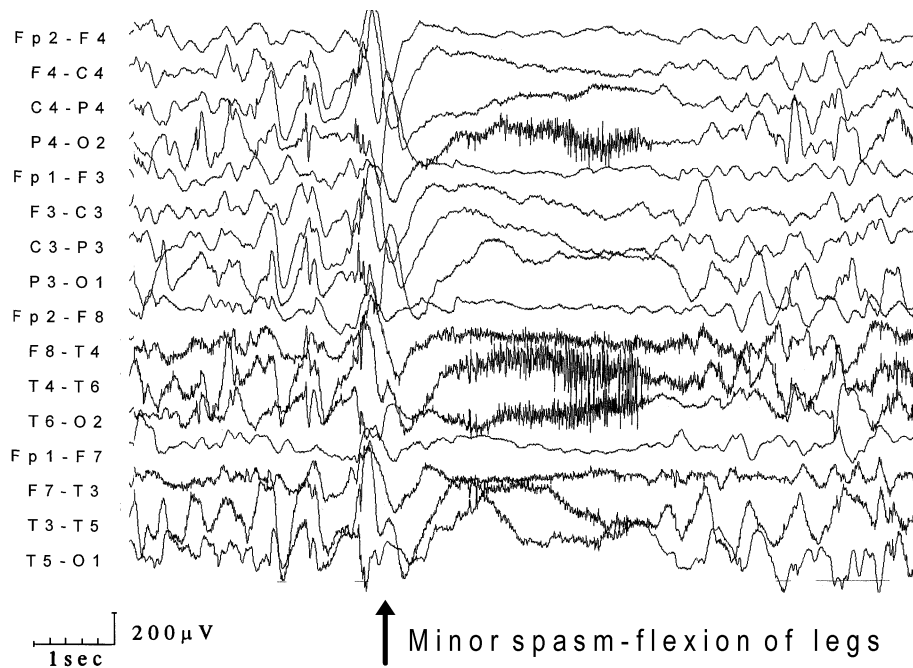


Figure 2. EEG from a child with Down syndrome and epileptic spasms. The initial EEG shows symmetrical hypsarrhythmia. The spasm coincides with a large amplitude slow wave followed by an electrodecremental response.

For many years West syndrome was recognised to occur in symptomatic and cryptogenic (probably symptomatic) forms. More recently it has been generally accepted that a true idiopathic form exists. At least 85% of cases are symptomatic (table). The single commonest cause is tuberous sclerosis. Idiopathic West syndrome is diagnosed when spasms are symmetrical, development, including visual responsiveness, has been normal prior to onset of spasms, no cause is found and the EEG consists of typical hypsarrhythmia with reappearance of the hypsarrhythmia between spasms in each cluster. Other cases are considered cryptogenic.

	<b>Disease Category</b>	<b>Examples</b>
<u>Prenatal Disorders</u>	<i>Neurocutaneous syndromes</i>	Tuberous sclerosis Sturge-Weber syndrome Incontinentia pigmenti
	<i>Chromosomal &amp; Genetic disorders</i>	Down Syndrome Miller-Dieker syndrome

	<i>Malformations of cortical development</i>	Fragile X syndrome X-linked infantile spasms Aicardi syndrome Lissencephaly Pachygyria Polymicrogyria Laminar heterotopias Hemimegalencephaly Schizencephaly Holoprosencephaly
	<i>Hypoxic-ischaemic insults</i> <i>Congenital infections</i>	Cytomegalovirus Rubella Toxoplasma
	<i>Metabolic disorders</i>	Pyridoxine dependency Amino and organic acidopathies Mitochondrial disorders
<u>Perinatal Disorders</u>	<i>Hypoxic ischaemic insults</i> <i>Hypoglycaemic brain damage</i> <i>Severe infections</i>	Meningitis Encephalitis
	<i>Birth trauma</i> <i>Intracranial haemorrhage</i>	
<u>Postnatal Disorders</u>	<i>Severe infections</i>	Meningitis encephalitis
	<i>Trauma</i> <i>Intracranial Haemorrhage</i> <i>Neurodegenerative Disease</i>	Early onset polio and leukodystrophies
	<i>Drugs</i>	Theophylline

**Table** Main causes of West syndrome. Most can also cause the Lennox-Gastaut syndrome

West syndrome is usually easily recognised but can be confused with a number of epileptic and non-epileptic disorders, including: benign (non-epileptic) myoclonus of infancy; benign neonatal sleep myoclonus; Sandifer's syndrome and; colic.

There are many treatment strategies for West syndrome. Conventional AEDs may have a role and in France high dose sodium valproate is often used first line. Pyridoxine is popular, particularly in Japan. However, in most countries the choice of initial treatment is usually between vigabatrin and steroid treatment. With regards steroids, preparations used most often are natural and synthetic ACTH given i.m. and oral prednisolone. Vigabatrin is particularly effective for spasms due to tuberous sclerosis. A recent UK multicentre trial comparing steroid and vigabatrin treatment for spasms not due to tuberous sclerosis found evidence in favour of the former, although this must be balanced against the potentially severe, even fatal adverse effects of steroids. Surgery has a role in cases due to focal brain pathology.

The prognosis is generally, but not universally, poor. 15-30% with cryptogenic and particularly idiopathic spasms may become seizure free and develop normally or near

normally. However, around 60% are left with intractable seizures (often Lennox-Gastaut syndrome) and two thirds have severe learning difficulties and/or behavioural problems.

### Dravet Syndrome (also called *Severe Myoclonic Epilepsy in Infancy*)

This epilepsy syndrome is increasingly recognised. It is more common in boys. It begins in the first year of life and affected children are previously normal. The first seizure is usually febrile. There may be nothing remarkable about the seizure but characteristically it is complex, being prolonged and/or focal. Febrile status is common. In addition, the provoking fever is often relatively mild. Indeed in some cases the child may simply be unwell without clear evidence of a fever. The child recovers as expected but further similar seizures usually occur, often becoming more and more frequent with time. Some are provoked by non-febrile illnesses, immunizations, hot baths and even hot weather. During this stage of the condition, development continues normally. A second stage then ensues, usually in the second or third years of life with a polymorphous epilepsy. Seizure types often include myoclonic seizures, febrile and non-febrile convulsive seizures (tonic-clonic, clonic or hemiconvulsions), atypical absences and focal seizures. Episodes of convulsive and non-convulsive status epilepticus may occur. As well as temperature provoking seizures, some patients are photosensitive. During this stage of the disease development stagnates and there is often a true regression. Neurological signs, such as ataxia and pyramidal signs commonly develop. Eventually all children are left with severe, often profound, learning difficulties. In late childhood a final stage ensues during which seizures tend to continue but are less frequent and development plateaus.

In Dravet syndrome the EEG is initially normal, except that about a fifth of subjects show very early photosensitivity. With the onset of the polymorphous seizure phase the EEG begins to slow and becomes dominated by diffuse theta and delta. Paroxysmal abnormalities of polyspike and/or spikes and slow waves usually become frequent occurring in brief bursts which are often asymmetrical.

Genetic factors are very important in Dravet syndrome, but the condition rarely recurs in families (although this is described) and it certainly does not follow simple Mendelian inheritance. A family history of epilepsy (of various types) is very common. Probably more than 50% of subjects with typical Dravet syndrome and a smaller, but still significant, number of atypical cases have mutations on the SCN1A gene which codes for a sodium channel. Given that the same mutations may be associated with much milder epilepsy phenotypes, it is clear that other genetic or environmental factors must be involved in producing the Dravet phenotype but these remain to be elucidated. Other investigations are expected to be normal, although diffuse atrophy may develop on brain imaging.

Response to AEDs is poor, although temporarily good results can be obtained from a number of agents. Carbamazepine, phenytoin and lamotrigine may exacerbate seizures and should be avoided. Stiripentol in conjunction with sodium valproate and/or clobazam has been shown to be beneficial in a double-blind, placebo controlled trial. The ketogenic diet may be useful.

### Migrating Focal Seizures of Infancy (also called *Malignant Migrating Partial Seizures in Infancy*)

This rare syndrome starts any time between birth and about 7 months in previously normal children. It is characterised by focal seizures with motor and prominent autonomic symptoms and with secondary generalised seizures. Seizures vary in their intensity and duration; episodes of status are common. The seizures tend to increase in frequency, becoming virtually continuous. EEG background is slow with varying side emphasis and multifocal spikes develop. Ictal discharges involve multiple independent sites, moving from one cortical area to

another. Investigations, except EEG are normal and the cause is unknown. Response to treatment is poor and there is a high mortality.

## Severe Epilepsy Syndromes of Childhood

The following epilepsy syndromes in childhood are often severe, constituting epileptic encephalopathies: Lennox-Gastaut syndrome; Doose syndrome; Landau-Kleffner syndrome and the related disorder of epilepsy with continuous spike and waves during slow-wave sleep; and myoclonic absence epilepsy. Note that the propensity of these syndromes to act as epileptic encephalopathies varies: Landau Kleffner syndrome always does so whilst Doose syndrome, which is classified as an idiopathic generalised epilepsy, sometimes does but often does not.

### Lennox-Gastaut syndrome

Probably no syndrome diagnosis is more abused and misunderstood than Lennox-Gastaut syndrome (LGS). Some authorities, particularly in the USA classify virtually all drug resistant epilepsies characterised by multiple seizure types as LGS. Used in this way, the diagnosis is of little use in helping management. The alternative, much favoured in Europe and increasingly in the UK, is to use a narrower definition of the syndrome. This approach will be used here.

LGS usually begins between 3 and 5 years of age, but can start as early as 1 year or as late as adolescence. Its incidence is said to be 2.8 per 10,000 live births but because of its intractable nature its prevalence in children with seizures may be up to 5%. It is characterised by seizures of multiple, mainly generalised, type and learning difficulties. The three most characteristic seizure types are tonic (particularly axial tonic seizures), atonic and atypical absence seizures. However, other seizure types may occur, including GTCS and focal seizures. Myoclonic seizures are not usually prominent, although they can occur. A so-called myoclonic variant of LGS is described in which myoclonic seizures are prominent. However, children with this may be better classified as Doose syndrome. Tonic seizures can occur both when awake and in sleep, but the latter are a particular feature of LGS. Tonic, atonic and to a lesser extent, myoclonic seizures frequently cause atstatic seizures (i.e. drop attacks) in LGS. Finally episodes of non-convulsive status epilepticus are common.

The background EEG in LGS is usually diffusely slow. Two main paroxysmal EEG features help in the diagnosis. These are (Fig 3):

- Slow (<2.5 Hz) spike and wave discharges which are usually generalised and symmetrical but can be asymmetrical, unilateral or even regional. They can be interictal or ictal. If the latter they can be associated with atypical absences or atonic seizures.
- Fast rhythms or rhythmic rapid spikes at frequencies of 10-20Hz which are usually seen in slow wave sleep. These may accompany tonic seizures.

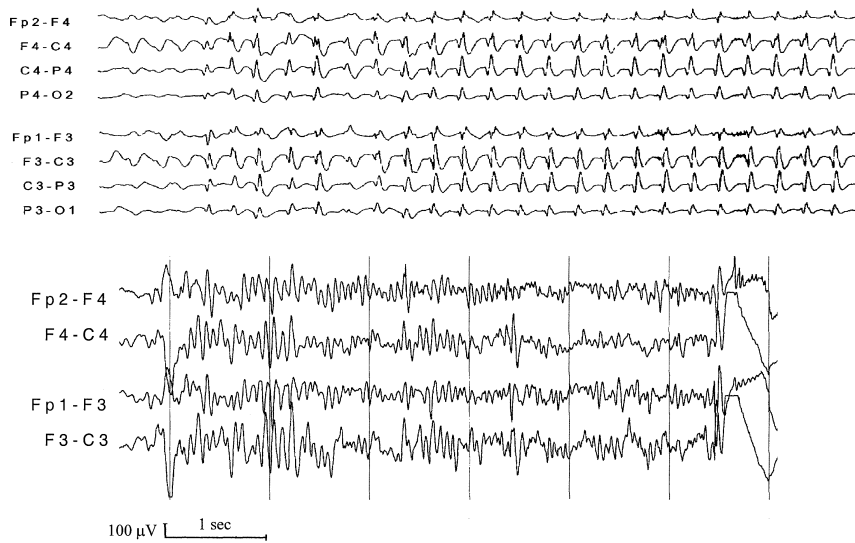


Figure 3. Upper EEG - Slow spike and wave discharge  
Lower EEG – Fast rhythms

LGS exists in symptomatic and cryptogenic (probably symptomatic) forms and probably also in an idiopathic form. The casues are similar to those seen in West syndrome (table), from which LGS sometimes evolves. Two thirds to three quarters of children with LGS have developmental problems prior to onset of seizures. This reflects the diverse aetiologies associated with LGS. With the onset of seizures development stagnates and at times of particularly frequent seizures, may regress. Nearly but not all children with LGS eventually have learning difficulties, usually severe. Behavioural problems are also very frequent. With increasing age some children become seizure free but many continue to have the phenotype of LGS into adult life or else develop a rather non-specific epilepsy with less frequent convulsive and non-convulsive seizures. Features which suggest a better prognosis include cryptogenic or idiopathic in type, more frequent myoclonic seizures, EEGs which feature some fast spike and/or polyspike and wave discharges, older age of onset and rapid control of seizures.

LGS is notoriously drug resistant, although some children will respond to AEDs, albeit often only temporarily. Drugs active against generalised seizures, particularly sodium valproate are usually used first. Benzodiazepines and lamotrigine can also be helpful, although the latter may exacerbate myoclonic seizures. Ethosuximide may help atypical absences in particular. Drugs such as carbamazepine and phenytoin should be used with particular caution as they may exacerbate some seizure types. Felbamate, Topiramate, lamotrigine and Rufinamide have all been shown in randomised controlled studies to be superior to placebo in LGS and both levetiracetam and zonisamide are also probably appropriate drugs to try. Non drug treatments which can be helpful include the ketogenic diet and vagal nerve stimulation. Very occasionally children develop LGS as a consequence of surgically remediable focal pathology. Callosotomy has an occasional role to play for the treatment of astatic seizures.

Doose Syndrome (also called *Epilepsy with Myoclonic-Astatic Seizures* or *Epilepsy with Myo-atonic seizures*)

This syndrome usually starts between 2 and 4 years of age, but can begin as early as the first year of life or up to mid childhood. Boys are affected more than girls and development is normal prior to the onset of seizures. It is now considered to be an idiopathic generalised epilepsy (IGE).

In most children with Doose syndrome the first seizures are febrile or afebrile GTCS. These are then followed by the characteristic seizure, the so-called myo-atonic seizure which combines a symmetrical myoclonic jerk immediately followed by an atonic seizure, usually causing a drop attack. Children with Doose syndrome may also have independent atonic and myoclonic seizures and brief typical absence seizures. Episodes of non-convulsive status epilepticus lasting hours or days occur in some children. Being an IGE, investigations other than EEG are expected to be normal. Interictal EEG may show rhythmic theta in the parasagittal regions, with frequent clusters of generalised spike-wave discharges at 2-3 Hz and/or polyspike or polyspike and wave discharges (Fig 4). These patterns may also be ictal.

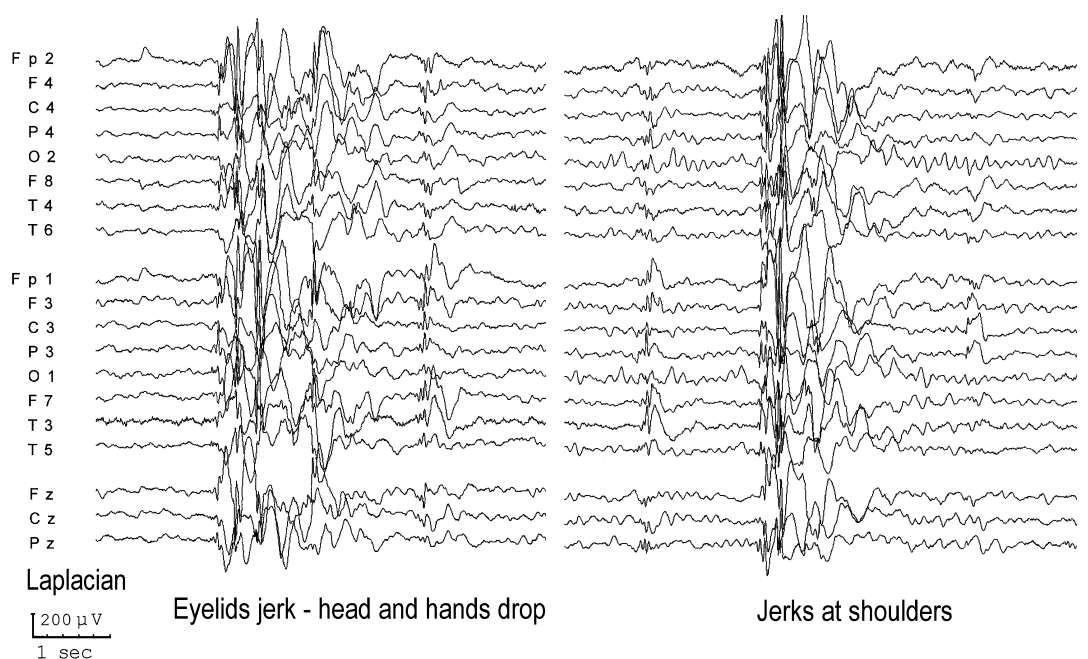


Figure 4. The EEG from a 6 year old boy with Doose syndrome

The prognosis is variable. Many, perhaps up to half of children with the syndrome become free of the drop attacks, although they may continue to have GTCS, and develop normally or near normally. In others drop attacks may continue for years and learning difficulties become apparent. It is these children with Doose syndrome who appear to have an epileptic encephalopathy.

The response to AEDs varies from complete responses to marked drug resistance. Drugs active against generalised epilepsies should be used. These include sodium valproate, topiramate, levetiracetam and benzodiazepines. Lamotrigine may also be helpful but there is concern that it can exacerbate myoclonic seizures. Drugs mainly active against focal seizures, such as carbamazepine may exacerbate seizures and should be avoided. Doose syndrome often responds very well to the ketogenic diet.

*Landau Kleffner Syndrome (also called Acquired Epileptic Aphasia) and Epilepsy with Continuous spike and waves during slow wave sleep (ECSWS) or Epileptic Encephalopathy with Electrical Status Epilepticus during Slow-Wave Sleep (ESES))*

These disorders overlap and therefore will be considered together. The Landau Kleffner syndrome (LKS) usually starts in otherwise normal children between 5 and 7 years of age but can start much earlier or later. It is more common in boys. It consists of a triad of: an acquired language problem; epileptic seizures and; behavioural problems. The language problem is initially auditory verbal agnosia such that the children find difficulty in attributing semantic value to speech. This is often very severe, causing the children to stop responding initially to the spoken word and sometimes to environmental noises as well. They are often suspected of being deaf. A secondary motor aphasia commonly develops. Epileptic seizures occur in three quarters of patients with LKS. The seizures can be of different types including GTCS and focal seizures. They are often, but not always, infrequent. The behavioural problems, often severe, include hyperactivity and attention deficits and autistic behaviours. The language problems, behavioural problems and seizures often fluctuate in their severity and this may correlate with the EEG findings.

The EEG is characterised by mainly posterior temporal lobe foci of sharp slow-wave complexes that are often multi-focal and bisynchronous. The awake EEG may be normal but non-REM sleep nearly always markedly increases the epileptiform abnormalities, such that they often occupy at least 85% of non-REM sleep. This constitutes electrical status epilepticus during slow wave sleep (ESES). Although ESES is very common in LKS it is not a pre-requisite and its presence may vary between EEGs.

Structural imaging in LKS is usually normal. Functional imaging often implicates the superior temporal gyrus, on one side or the other.

The LKS nearly always eventually remits. Occasionally this can be after only a few weeks or months. More often it continues for some years and adults are usually left with persistent language and cognitive problems, although these are often milder than would be anticipated during the active stage of the condition.

Seizures in LKS often respond well to conventional AEDs but often without improvement in language function or behaviour. However, sodium valproate is often used first line and both ethosuximide and benzodiazepines can be helpful. Some children respond very well to treatment with steroids. If medical treatment fails the neurosurgical technique of multiple subpial transections can be very beneficial. It requires the area of cortex 'driving' the problem to be identified. Multiple cortical cuts are made tangentially to the surface disrupting horizontal fibres responsible for seizure propagation whilst leaving vertical fibres responsible for normal functioning intact.

Epilepsy with Continuous spike and waves during slow wave sleep (ECSWS) is a related and overlapping epilepsy syndrome which can start from 2 months to 12 years. Many children are neurodevelopmentally normal prior to the onset of seizure but others have a variety of developmental problems, including cerebral palsy and learning difficulties. The condition usually starts with seizures which are often nocturnal and hemi convulsive in type. They may be prolonged constituting status epilepticus. Usually after months or years the seizures increase in frequency and become polymorphous. Indeed all types of seizures may occur during this stage, except probably tonic seizures. With the increase in seizures neuropsychological regression occurs and may be severe. There may be, in addition, acquired

motor deficits such as ataxia, hemiparesis and dyspraxia. An opercular syndrome with drooling, feeding problems and dysarthria can occur.

The EEG hallmark of ECSWS is continuous (i.e. >85%), bilateral and diffuse spike and waves during non-REM sleep.

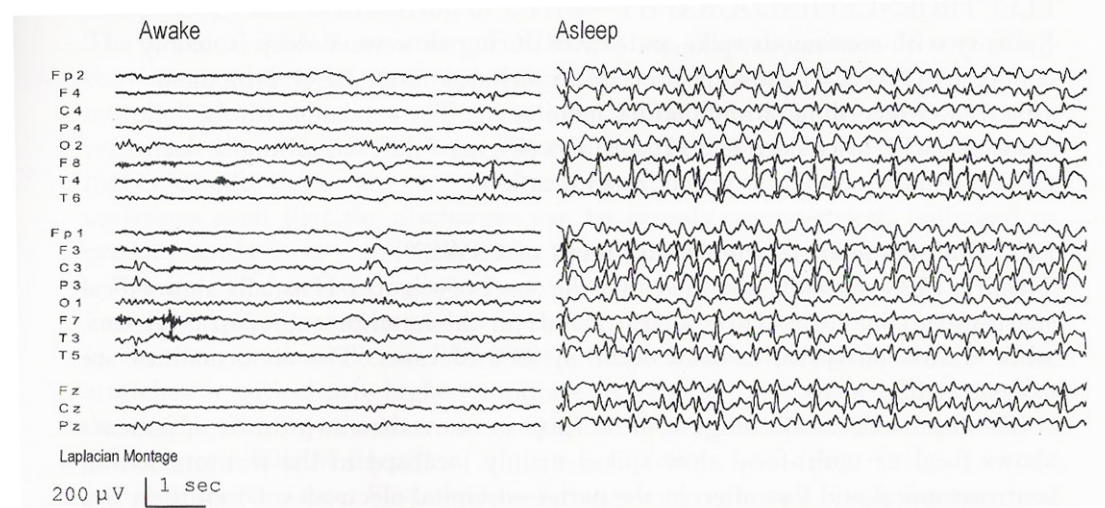


Figure 5. The EEG from a boy with Rolandic epilepsy who developed continuous spike and wave during slow wave sleep

Many children with ECSWS have structural brain abnormalities. In others the condition develops in previously normal children. It is a rare complication of benign childhood epilepsy with centro-temporal spikes (Rolandic epilepsy) and other idiopathic focal epilepsies of childhood. Carbamazepine has been implicated as precipitating it in some cases. Treatment is similar to LKS and as for LKS the condition appears to eventually remit, but usually leaving significant neurodevelopmental problems.

### Epilepsy with Myoclonic Absences

Epilepsy with myoclonic absences (EMA) is a rare epilepsy syndrome which can start at any time in childhood. The hallmark is myoclonic absence seizures. These are similar to typical absence seizures but with superimposed rhythmic myoclonic jerks mainly of the upper limbs. The jerks can be mild or severe. GTCS and atonic seizures may also occur. The EEG shows a normal background with 3 Hz generalised spike and wave discharges. Simultaneous EMG demonstrates the myoclonic jerks. Marked asymmetries and focal abnormalities may be apparent. Slowing of the background may occur later.

EMA is now classified as an IGE by the ILAE but most children with myoclonic absences have pre-existing neurodevelopmental problems and a variety of underlying aetiologies including structural brain defects and chromosomal abnormalities. Impaired cognitive functioning commonly develops even in those children who were normal prior to the onset of the seizures. There is some evidence that successful treatment of the seizures prevents or minimises this. Drugs active against absence seizures in general should be tried and drugs such as carbamazepine mainly active in focal epilepsies should be avoided. Relative seizure resistance is the rule.

### **Some aetiologies associated with severe childhood epilepsies**

Some pathological entities are associated with a high likelihood of intractability. These are not epilepsy syndromes (although some are syndromes as used in the more general sense) but for completeness will be briefly described here.

*Rasmussen's encephalitis (also known as Kojewnikov's encephalitis and Rasmussen syndrome)*

This very rare epilepsy usually begins with focal motor seizures, often very localised at least initially. Episodes of focal motor status (epilepsy partialis continuans) is common. Other seizure types, including GTCS may occur. Over a period which can be only a matter of weeks or else years, a progressive hemiplegia develops along with cognitive decline. Untreated the disease eventually remits but usually leaving a dense motor deficit and severe learning difficulties. Pathologically there is focal perivascular infiltrates characteristic of a viral or autoimmune process: the cause, however, remains unknown. Early structural scans may be normal or may show focal signal abnormalities. Later hemiatrophy develops. Some reports suggest that bihemispheric involvement may occur but this is controversial. Some response to conventional AEDs may occur, but nearly always this is temporary. Immunological treatments, such as steroids and intravenous immunoglobulin are usually used, sometimes with apparent success. However, most patients eventually require hemispherectomy.

*Abnormalities of Cortical Development*

Cortical dysplasias vary greatly in their epileptogenicity. This is perhaps best illustrated by tuberous sclerosis. Many subjects with this live normal lives, others have mild epilepsies and are of normal or near normal intelligence. However, many children with tuberous sclerosis present very early on in life with severe epilepsies, particularly West syndrome and are devastated by the disorder.

Hemimegalencephaly is a particularly severe and complex dysplasia affecting one hemisphere (although less severe abnormalities of the 'uninvolved' hemisphere may be present. It often presents with refractory focal and secondarily generalised seizures in early life. Early hemispherectomy maximises developmental potential.

*Dysembryoplastic neuroepithelial tumours*

These are indolent cortical brain tumours which include both neural and glial elements. Most are temporal in origin but any cortical region can be involved. They may be congenital. They commonly present in childhood or early adult life with focal epilepsy, which has a tendency to be refractory to medical treatment. There is evidence that the early surgical resection not only controls seizures but improves neurodevelopmental outcome in those children who present at an early age with intractable seizures.

*Sturge-Weber Syndrome*

This neurocutaneous disorder features a facial port wine stain with an ipsilateral pial angioma. The clinical consequences are highly variable. However, a minority of infants with it develop: refractory focal seizures, including episodes of potentially devastating status epilepticus; progressive hemiplegia; and progressive cognitive decline. The last two of these appear to be caused by a vascular steal phenomenon related to the pial angioma causing atrophy of the underlying cortex. Surgical treatment with lobar, multilobar or hemispheric resection may halt this progression.

