

Neonatal seizures

RONIT M. PRESSLER

Department of Clinical Neurophysiology, Great Ormond Street Hospital, London

Introduction

The immature brain seems more prone to seizures than the more mature brain. Seizures are more common in the neonatal period than during any other time throughout life. Seizures in the neonatal period are also the most common neurological emergency and are associated with high mortality and morbidity^{1,2}.

The incidence of seizures in infants born at term is 1–3 per 1000 live births; the incidence is even higher in preterm infants, ranging from 1–13% of very low birthweight infants³. Such discrepancies can be explained by different diagnostic definitions and methods used. Most of these epidemiological studies include only clinical seizures. The exact incidence of electrographic, clinically silent seizures is as yet unknown. The majority of neonatal seizures occur on the first day, and 70% of all cases eventually recognised have been diagnosed by the fourth day.

Aetiology

Many causes can give rise to neonatal seizures (Table I), although only a few of these conditions account for most seizures. Few seizures are idiopathic. Several decades ago, late

Table I. Causes of neonatal seizures³⁻⁵.

Cause	Frequency
Hypoxic-ischaemic encephalopathy	30–53%
Intracranial haemorrhage	7–17%
Cerebral infarction	6–17%
Cerebral malformations	3–17%
Meningitis/septicaemia	2–14%
Metabolic	
Hypoglycaemia	0.1–5%
Hypocalcaemia, hypomagnesaemia	4–22%
Hypo-/hypernatraemia	
Inborn errors of metabolism (such as pyridoxine dependency, folinic acid-responsive seizures, glucose transporter defect, non-ketotic hyperglycinaemia, propionic aciduria)	3–4%
Kernicterus	1%
Maternal drug withdrawal	4%
Idiopathic	2%
Benign idiopathic neonatal seizures	1%
Neonatal epileptic syndromes	
Congenital infections	

hypocalcaemia due to a low calcium:phosphate ratio in baby formula was a frequent cause of neonatal seizures but this is very rare today. At term, hypoxic ischaemic encephalopathy is the most common underlying factor, typically with onset in the first 24 hours of life. In preterm infants, intracranial haemorrhage is the most common cause. Meningitis, focal cerebral infarction, metabolic disorders and congenital abnormalities of the brain can cause seizures at any gestation.

Mechanism

The developing brain is particularly susceptible to developing seizures in response to injury; several mechanisms are likely to be involved. Overall the hyperexcitable state of the immature brain is based upon enhanced excitatory neurotransmission, paucity of inhibitory mechanisms, developmental expression of neuronal ion channels, age-dependent modulation of neuropeptides and age-dependent early microglial activation. In the immature brain there is a relative excess of excitatory neurotransmitters and receptors^{6,7}. The arborisation of axons and dendritic processes as well as myelination are incomplete in the neonatal brain resulting in weakly propagated, fragmentary seizures whose electrical activity may not spread to surface EEG electrodes. Generalised tonic-clonic seizures are rare in the first month of life and not seen in the preterm infant. Neonatal seizures are usually focal, often short lasting (see EEG). The development within the limbic system with connections to midbrain and brainstem is more advanced than the cerebral cortical organisation, leading to a higher frequency of mouthing, eye deviation, and apnoea in neonates than seizures in adults.

Clinical manifestation and classification

Even among trained observers, clinical neonatal seizures may be difficult to recognise and differentiate from either normal behaviours or abnormal movements of non-epileptic origin⁸. Additional problems arise when the relationship between clinical and electroencephalographic seizures is considered. At times, there is temporal overlap of the two (so-called 'electroclinical seizures'). However, in some clinical settings up to 85% of electrographic seizures are clinically silent (i.e. only electroencephalographic seizure activity present with no clinical accompaniment, referred to as 'electrical only seizures'), leading to significant underestimation of seizure burden⁹. For these reasons, in the broadest terms a seizure in this age group is best defined either in clinical terms as an abnormal paroxysmal event (with or without EEG seizure activity) or electrographically as a sustained epileptiform change in the EEG, which may or may not be accompanied by paroxysmal alteration in neurological function.

As aetiology and presentation of neonatal seizures is different to seizures in older children and adults, they do not easily fit into the 1981 ILAE classification of epileptic seizure types or the 1989 ILAE classification of epilepsy syndromes and epilepsies. Several classifications have been proposed, of which the classifications by Volpe³ (according to clinical features only) and by Mizrahi and Kellaway^{4,10} (according to pathophysiology: epileptic or non-epileptic origin) are more widely used (Table II).

The Mizrahi classification has the advantage that it takes the origin of events into account and includes clinically silent electrographic seizures. According to the Volpe classification seizures can be subtle, myoclonic, clonic or tonic. Subtle seizures are the most common seizure type in both preterm and term babies. Manifestations include:

- Ocular phenomena (staring, blinking, eye deviation, eye opening)
- Oral phenomena (mouthing, chewing, sucking, smiling)

Table II. Classification of neonatal seizures.

(1) adapted from Volpe³		
Type	Characterisation	Ictal EEG abnormalities
Subtle	Ocular, oral-buccal-lingual, autonomic, apnoea, limb posturing and movements	Variable
Clonic	Repetitive jerking, distinct from jittering. Unifocal or multifocal	Common
Myoclonic	Rapid isolated jerks. Focal, multifocal or generalised	Common if generalised, uncommon if focal
Tonic	Stiffening. Decerebrate posturing. Focal or generalised	common if focal, uncommon if generalised

(2) adapted from Mizrahi and Kellaway^{4,10}		
Type	Characterisation	Epileptic origin
Focal clonic	Rhythmic muscle contractions	✓
Focal tonic	Sustained posturing of limb/trunk	✓
Myoclonic	Random single contractions	✓/-
Spasms	Flexor or extensor, ± in clusters	✓
Electrographic	By definition none	✓
Generalised tonic	Sustained symmetric posturing	-
Motor automatism	Ocular, oral-buccal-lingual or progression movements of limbs	-

- Autonomic phenomena (change in blood pressure and/or heart rate, pallor, increased salivation or secretions; central apnoea occurring rarely as the only seizure manifestation)
- Fragmentary body movements (limb posturing, swimming, pedalling).

Similar phenomena and motor behaviours occur in neonates, especially in premature infants and encephalopathic infants. Although they are often less stereotyped and may be suppressed by restraints or triggered by stimulation, these are clinically very difficult to diagnose⁵. Prolonged video-EEG has clearly shown that the majority of infants with subtle seizures will exhibit ictal rhythmic epileptiform activity^{4,11}. The absence of ictal EEG discharges makes an epileptic origin of these movements less likely. This issue has been addressed in the Mizrahi classification: motor automatisms without clonic or tonic components and without EEG correlate are not considered to be of epileptic origin.

Clonic seizures can be focal, multifocal migrating from limb to limb or, rarely, hemiconvulsive. Jacksonian march is exceptional in neonates, but may be seen in babies with stroke. These seizures are most likely to be correctly diagnosed clinically¹². However, they may be difficult to differentiate from non-epileptic movements, like jitteriness, tremors or shudders. These non-epileptic movements can be suppressed by gentle restraint and may be enhanced by sensory stimuli. There is good correlation with EEG changes.

Erratic, fragmentary or more generalised myoclonic jerks are often associated with tonic spasms, with multifocal clonic or tonic patterns, or with mixed seizure types. They may persist into infancy (infantile spasms). Myoclonic seizures can easily be distinguished from benign neonatal sleep myoclonus by the absence of myoclonia during wakefulness and a normal EEG.

Focal tonic seizures are characterised by stereotyped, abrupt or slower tonic posturing of limb, and/or trunk or eyes, often accompanied by apnoea, flushing, or mild cyanosis. The EEG background is often abnormal and ictal discharges are common. Although still considered in the Volpe seizure classification, generalised tonic posturing is unlikely to be epileptic seizures, but rather to represent transient decerebrate or decorticate posturing, which can be triggered by stimulation and show no ictal EEG correlates. EEG background activity is severely abnormal and the outcome is poor. This seizure type is not classified as being of epileptic origin in the Mizrahi classification.

A characteristic feature of neonatal seizures is the phenomenon of electro-clinical dissociation: seizures can be electroclinical, electrographic (subclinical) or clinical only¹³. The significance of clinical only seizures is unclear. There is an ongoing controversy as to whether electrical-only seizures have an impact on long-term outcome and thus require treatment or not. There is now evidence that they have a similar impact on long-term outcome as electro-clinical seizures¹⁴.

Investigations

The large differential diagnosis following a neonatal seizure (Table II) demands that the initial investigations should concentrate on the common aetiologies requiring prompt specific treatment. Certain clues to the aetiology may be present, such as a history of perinatal asphyxia or maternal narcotic abuse, but other causes such as hypoglycaemia, hypocalcaemia, and CNS infection may coexist and need excluding. Investigations include:

- Septic screen, including blood cultures and lumbar puncture
- Laboratory: always glucose, electrolytes, blood gas, packed cell volume, if necessary bilirubin, ammoniac, metabolic screening, TORCH, screening for drug abuse
- Consider therapeutic trial of pyridoxine and pyridoxal phosphate
- Always cranial ultrasound scanning, consider MRI
- EEG.

Neuroimaging

Cranial ultrasound scanning is readily available in most centres and is useful as a first-line imaging investigation for exclusion of gross CNS pathology (CNS malformations, periventricular haemorrhage). If initial ultrasound examination is normal, but the infant continues to have seizures or has abnormal inter-ictal neurological signs, a CT or MRI examination has to be carried out to detect other forms of clinically important pathology, such as cerebral infarction, subdural and subarachnoid haemorrhage or cerebral malformations.

EEG

EEG definitions vary, but paroxysms are considered to be seizures if they last more than 10 seconds. Neonatal electrographic seizures are often not sustained. The typical duration of the electrographic neonatal seizure is 2–3 minutes¹⁵, but many seizures will be shorter, particularly in preterm infants¹⁶. In spite of this, the total seizure burden can be very significant. Neonatal seizures have a focal onset, whereas a generalised onset spike and wave seizure discharge is extremely rare. Neonates can display simultaneous independent focal electrographic seizures (Fig. 1). Neonatal status is currently defined as a total seizure time occupying 50% of a recording. Abnormal background activity is associated with an increased risk of seizures¹⁷ and poor neurodevelopmental outcome.

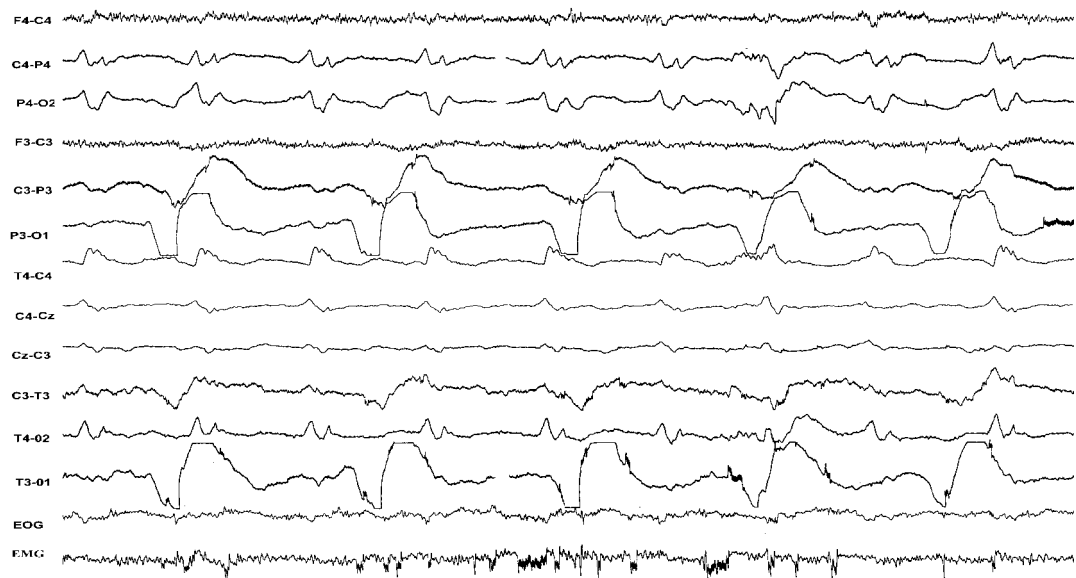


Figure 1. Characteristic features of neonatal seizures: two simultaneous, but quite different seizure pattern discharges over right and left hemispheres. There were no obvious clinical manifestations (an example of electro-clinical dissociation).

Discharges of less than 10 seconds' duration have been termed BIRDs (brief inter-ictal rhythmic discharges or brief ictal rhythmic discharges) and are of uncertain significance. However, BIRDs have been associated with seizures in the same or subsequent EEG and with poor neurodevelopmental outcome¹⁸.

EEG can provide confirmation that any suspicious phenomena are seizures. However, not all clinically observed seizures are detected by EEG and many neonatal seizures are subclinical (electro-cortical disassociation). Two explanations have been proposed: (1) some seizures may originate at a subcortical level and are not propagated to surface electrodes because of the immature synaptogenesis and cortical projections¹⁹ and (2) some subtle and tonic seizures might not be epileptic but are primitive brain stem and spinal motor phenomena¹⁰.

Cerebral function monitoring

The cerebral function monitor (CFM) has the advantage that it is widely available, and interpretation using pattern recognition can easily be learned. However, short seizures (<30 seconds) cannot be detected, low amplitude or focal seizures are easily missed and movement artefacts are difficult to exclude and may look like seizures²⁰. Thus, in neonates CFM is prone to false-negative and false-positive errors. Non-experts are prone to false negative errors and the inter-observer agreement is low^{21,22}.

Epileptic syndromes

Benign idiopathic neonatal convulsions (fifth-day fits)

Benign idiopathic neonatal convulsions occur around the fifth day of life (day 1 to day 7, with 90% between day 4 and 6) in otherwise healthy neonates. At present the aetiology is unknown. Seizures are clonic, mostly partial and/or apnoeic²³. The inter-ictal EEG shows 'théta pointu alternant' in 60%, in the remaining neonates the background activity is either discontinuous, with focal or multifocal abnormalities, or normal. Ictal recordings show unilateral or generalised rhythmic spikes or slow-waves. Treatment may not be necessary,

but the diagnosis is one of exclusion. Seizures usually resolve within days. The outcome is good, but increased risk of minor neurological impairment has been reported^{24,25}.

Benign familiar neonatal convulsions

Benign familiar neonatal convulsions constitute a rare disorder with autosomal dominant inheritance (mutations in the voltage-gated potassium channel genes: most cases 20q13.3, few families 8q24). Seizures occur mostly on the second or third day of life in otherwise healthy neonates and tend to persist longer than in benign idiopathic neonatal convulsions. They are mainly clonic, sometimes with apnoeic spells; tonic seizures have rarely been described. The background activity is normal with no specific pattern. Therapy is controversial and seizures usually resolve within weeks. The outcome is favourable, but secondary epilepsy may occur²³.

Early myoclonic encephalopathy

Early myoclonic encephalopathy²⁶ is a syndrome often associated with inborn errors of metabolism, but cerebral malformations have also been reported. Onset is nearly always in the first month of life and ictal manifestations are as follows: (1) partial or fragmented myoclonus; (2) massive myoclonias; (3) partial motor seizures; (4) tonic spasms. Background activity is abnormal consisting of complex bursts of spikes and sharp waves lasting for 1–5 seconds alternating with flat periods of 3–10 seconds in both waking and sleep. The EEG later evolves towards atypical hypsarrythmia. Seizures are resistant to treatment, though ACTH may have some temporary effect. All infants are severely neurologically abnormal and half of them die before the age of one year.

Early infantile epileptic encephalopathy with burst-suppression pattern (Ohtahara syndrome)

Age of onset is in the first three months of life with frequent tonic spasms (100–300 per day), often in clusters²⁷. Partial motor seizures may also occur. The EEG is characterised by true burst-suppression pattern, both in sleep and waking. It may be asymmetric. During seizures desynchronisation is seen. This syndrome is usually associated with cerebral malformations, e.g. Aicardi syndrome or porencephaly. Seizures are resistant to treatment, though ACTH may have some temporary effect. The prognosis is serious, but may be somewhat better than for early myoclonic encephalopathy. Evolution into infantile spasms is common.

Both EME and Ohtahara syndrome have clinically and electrographically distinct features. However, there are also similarities, which have prompted some to suggest that they are not two syndromes, but rather part of a spectrum of a single disorder²⁶.

Glycine encephalopathy (neonatal non-ketotic hyperglycinaemia)

This inborn error of metabolism usually presents as an early myoclonic encephalopathy (see above) with seizures (myoclonus elicited by tactile and painful stimuli) on the second or third day of life. Associated respiratory distress syndrome, with periodic respiration, and coma are found. The EEG shows unusual periodic discharges on a near silent background²⁸.

Glucose transporter type 1 syndrome

Glucose transporter deficiency is a cause of seizures starting in the first three months of life, with mixed seizure types, postnatal microcephaly and encephalopathy later in the first year of life²⁹.

Pyridoxine dependency

Pyridoxine dependent seizures are a rare but treatable subgroup of neonatal seizures, which can begin in intrauterine life³⁰. Seizures of multiple types usually begin shortly after birth and are resistant to conventional antiepileptic drugs (AEDs). There may be encephalopathy

and/or structural brain abnormalities. The EEG shows burst-suppression pattern, which may be interrupted by focal seizures or other generalised epileptiform activity. Pyridoxine/pyridoxine-5-phosphate is required for the synthesis of several neurotransmitters, including gamma amino butyric acid (GABA), monoamines and others. Mutations in the ALDH7A1 gene, which encodes antequitin, were recently described in some children with pyridoxine-dependent seizures and linkage to 5q31 in some affected families. Pilocolic acid in plasma and cerebrospinal fluid is considered a possible metabolic marker for this disorder³⁰. When pyridoxine dependency is suspected, 100–200 mg of pyridoxine should be given intravenously under EEG control. The seizures will abruptly stop (within minutes) and the EEG will normalise during the next few hours. Acute suppression of EEG activity occurs occasionally and may be associated with acute cardiovascular collapse. A subgroup of affected babies responds only to very high doses given for two weeks. A closely related disorder with a similar clinical picture has now been identified as pyridoxal-5-phosphate dependent seizure.

Folinic acid responsive seizures are a rare cause of neonatal seizures with clinically similar features to pyridoxine dependent seizures³⁰.

Seizures in hypoxic-ischaemic encephalopathy

Hypoxic ischaemic encephalopathy (HIE) is a common and important cause of seizure in neonates born at term. The characteristic time of onset of seizures in HIE is 8–36 hours after birth. Seizures occurring before that are usually ‘clinical only’ and are due to an abnormal increase in tone. This appears to be similar to animal studies in which the EEG activity in lambs with an intrapartum insult is at first depressed, and then evolves to show seizure activity about eight hours after birth³¹. An EEG obtained shortly after birth in which electrographic seizure activity was already manifest, would strongly suggest an insult over eight hours before delivery. Early background EEG activity is a relatively reliable prognostic indicator for outcome^{32,33}.

Treatment

Phenobarbitone remains the drug of choice in the treatment of neonates. The initial dose is 20 mg/kg in unventilated babies and 30 mg/kg in those who are ventilator-dependent (Table III), aiming to achieve a serum level of 90–180 µmol/L. Phenobarbitone achieves clinical control in only 30–40% of cases³⁴; some claim better clinical control with doses of up to 40 mg/kg and serum levels above 180 µmol/L³⁵. There is, however, evidence that phenobarbitone increases the electroclinical dissociation: while the number of electroclinical seizures decreases, the number of electrographic seizures increases^{36,37}. It has been suggested that this is due to a time difference of the GABA switch which is earlier in thalamic compared to neocortical neurons³⁸.

Phenytoin and clonazepam are used as second-line AEDs. Phenytoin can cause significant myocardial depression and should be avoided in babies requiring inotropic support. Clonazepam may achieve better EEG control. Midazolam³⁹ has a shorter half-life than clonazepam and does not accumulate, and it avoids the side effect of increased oropharyngeal secretions. Others have reported success with lignocaine⁴⁰: between 70% and 92% of newborns responded to lignocaine as second-line AED^{41–43}. However, all these studies were uncontrolled, apart from one with small numbers⁴². Lignocaine has a narrow therapeutic range and can induce seizures in high doses. There is little experience with carbamazepine, vigabatrin and lamotrigine in the neonatal period. Consider a trial of pyridoxine, pyridoxal-5-phosphate and folinic acid.

Table III. Antiepileptic drug dose in the newborn.

Drug	Initial dose	Route	Maintenance	Route	Therapeutic level
Phenobarbitone	20–40 mg/kg	iv	3–5 mg/kg	iv/im/o	90–180 µmol/L
Phenytoin	15–20 mg/kg	iv/20 min	3–5 mg/kg	iv/o	40–80 µmol/L
Lorazepam	0.05–0.1mg/kg	iv	every 8–12 hrs	iv	
Diazepam	0.2–0.5 mg/kg	iv	every 6–8 hrs	iv	
Clonazepam	0.1 mg/kg	iv/30 min			30–100 mg/L
Midazolam	0.1–0.2 mg/kg	iv	0.1–0.3 mg/kg/h	iv	
Lignocaine	2 mg/kg	iv	1–6 mg/kg/h	iv	3–6 mg/l
Valproate	10–20 mg/kg	iv/o	20 mg/kg	O	275–350 µmol/L
Paraldehyde	0.1–0.2ml/kg	pr			
Pyridoxine (B6)	50–100mg	iv	100 mg every 10 min (up to 500 mg)		

A recent Cochrane report has reviewed the treatment of neonatal seizures⁴⁴. Only two randomised controlled studies were identified using adequate methodology^{34,42}, both indicating that current first-line treatment was only effective in about 40–50% of babies. For a review on AED treatment of neonatal seizures see Riviello^{45,46}.

Prognosis

This is mainly determined by the aetiology. The prognosis after hypocalcaemic seizures and in familial neonatal seizures is excellent. Symptomatic hypoglycaemia and meningitis have a 50% chance of sequelae in the survivors⁴⁷. In hypoxic ischaemic encephalopathy the prognosis depends very much on the grade (overall 30–50% normal), while CNS malformations are generally associated with poor outcome. Very low birthweight infants with clinical seizures have a higher incidence of impairment than preterm infants without seizures⁴⁸.

There is increasing evidence that neonatal seizures have an adverse effect on neurodevelopmental outcome, and predispose to cognitive, behavioural, or epileptic complications in later life. In animal studies, seizures impair neurogenesis and derange neuronal structure, function and connectivity leading to permanent effects on seizure susceptibility, learning and memory⁴⁹. Recent work has also shown how even a single seizure in the neonatal period may lead to long-term neuro-developmental consequences⁵⁰.

Undetected and untreated seizure activity increases the insult to the neonatal brain⁵¹. Seizures add to the hypoxic-ischaemic insult in newborn animals, and the same may be true for babies^{1,52}.

More recently a clear association between the number of electrographic seizures and subsequent mortality and morbidity has been shown¹⁴, illustrating the need for EEG monitoring in neonatal seizures.

However, there is increasing concern about the potentially adverse effects of AEDs on the developing nervous system. In animal models, phenobarbitone has been shown to cause additional brain damage by increasing neuronal death (apoptosis)^{53,54}. Better treatments for neonatal seizures have been identified as a high priority for research by several international expert groups, with emphasis on innovative strategies targeted specifically to the needs of babies with the ultimate aim to improve long-term outcome.

References

1. MILLER SP, WEISS J, BARNWELL A et al. Seizure-associated brain injury in term newborns with perinatal asphyxia. *Neurology* 2002; 58: 542-548.
2. DAVIS AS, HINTZ SR, VAN MEURS KP et al. Seizures in extremely low birth weight infants are associated with adverse outcome. *J Pediatr* 2010; 157: 720-725.
3. VOLPE JJ. Neonatal seizures. In: *Neurology of the Newborn* (5th Ed), Volpe JJ (Ed), pp 203-204. WB Saunders, 2008.
4. MIZRAHI EM, KELLAWAY P. *Diagnosis and Management of Neonatal Seizures*. 1st Edition. Philadelphia, Lippincott-Raven, 1998.
5. LEVENE MI, TROUNCE JQ. Causes of neonatal convulsions. *Arch Dis Child* 1986; 61: 78-79.
6. BEN ARI Y, HOLMES GL. Effects of seizures on developmental processes in the immature brain. *Lancet Neurol* 2006;5:1055-1063.
7. JENSEN FE. Neonatal seizures: an update on mechanisms and management. *Clin Perinatol* 2009; 36: 881-900.
8. MALONE A, RYAN CA, FITZGERALD A et al. Interobserver agreement in neonatal seizure identification. *Epilepsia* 2009; 50: 2097-2101.
9. MURRAY DM, BOYLAN GB, ALI I et al. Defining the gap between electrographic seizure burden, clinical expression and staff recognition of neonatal seizures. *Arch Dis Child Fetal Neonatal Ed* 2008; 93: F187-F191.
10. MIZRAHI EM, KELLAWAY P. Characterization and classification of neonatal seizures. *Neurology* 1987; 37: 1837-1844.
11. BOYLAN GB, PRESSLER RM, RENNIE JM et al. Outcome of electroclinical, subclinical and clinical seizures in the newborn infant. *Dev Med Child Neurol* 1999; 41: 819-825.
12. MURRAY DM, BOYLAN GB, ALI I, RYAN CA, MURPHY BP, CONNOLLY S. Defining the gap between electrographic seizure burden, clinical expression and staff recognition of neonatal seizures. *Arch Dis Child Fetal Neonatal Ed* 2008. 93: F187-F191.
13. WEINER SP, PAINTER MJ, GEVA D et al. Neonatal Seizures: Electroclinical dissociation. *Pediatric Neurol* 1991; 7: 363-368.
14. MCBRIDE MC, LAROA N, GUILLET R. Electrographic seizures in neonates correlate with poor neurodevelopmental outcome. *Neurology* 2000; 55: 506-513.
15. CLANCY RR, LEDIGO A. The exact ictal and interictal duration of electroencephalographic neonatal seizures. *Epilepsia* 1987; 28: 537-541.
16. SCHER MS, HAMID MY, STEPPE DA et al. Ictal and interictal electrographic seizure durations in preterm and term neonates. *Epilepsia* 1993; 34: 284-288.
17. LAROA N, GUILLET R, BURCHFIELD J et al. EEG Background as predictor of electrographic seizures in high-risk neonates. *Epilepsia* 1998; 39: 545-551.
18. OLIVEIRA AJ, NUNES ML, HAERTEL LM et al. Duration of rhythmic EEG pattern in neonates: new evidence for clinical and prognostic significance of brief rhythmic discharges. *Clin Neurophysiol* 2000; 111: 1646-53.
19. DANNER R, SHEWMON DA, SHERMAN MP. Seizures in the atelencephalic infant. Is the cortex essential for neonatal seizures? *Arch Neurol* 1985; 42: 1014-1016.
20. HELLSTROM-WESTAS L. Comparison between tape recorded and amplitude integrated EEG monitoring in sick newborn infants. *Acta Paediatrica* 1992; 81: 812-819.
21. RENNIE JM, CHORLEY G, BOYLAN G et al. Non-expert use of the cerebral function monitor for neonatal seizure detection. *Arch Dis Child* 2004; 89: F37-F40
22. SHELLHAAS RA, SOAITA AI, CLANCY RR. Sensitivity of amplitude-integrated electroencephalography for neonatal seizure detection. *Pediatrics* 2007; 120: 770-777.
23. PLOUIN P. Benign idiopathic neonatal convulsions (familial and non-familial). In: *Epileptic Syndromes in Infancy, Childhood and Adolescence* (2nd ed), Roger J et al (Eds), pp 3-11. John Libbey, London 1992.
24. DEHAN M, GABILAN JC, NAVELET Y, D'ALLEST AM. Fifth day fits. *Arch Dis Child* 1982; 57: 400-401.
25. NORTH KN, STOREY GN, HENDERSON-SMART DJ. Fifth day fits in the newborn. *Aust Paediatr J* 1989; 25: 284-287.
26. AICARDI J, OTOHARA S. Severe neonatal epilepsies with burst suppression pattern. In: Roger J et al (Eds), *Epileptic Syndromes in Infancy, Childhood and Adolescence*, (4th edition), pp 39-50. John Libbey, London, 2005.
27. YAMATOJI Y, OTHAHARA S. Early-infantile epileptic encephalopathy with suppression-burst, Ohtahara syndrome; its overview referring to our 16 cases. *Brain Dev* 2002; 24: 13-23.
28. SCHER MS, BERGMAN I, AHDAB-BARMADA M, FRIA T. Neurophysiological and anatomical correlations in neonatal nonketotic hyperglycinemia. *Neuropediatrics* 1986; 17: 137-143.
29. THARP BR. Neonatal seizures and syndromes. *Epilepsia* 2002; 43 (Suppl 3): 2-10.
30. WOLF NI, BAST T, SURTEES R. Epilepsy in inborn errors of metabolism. *Epileptic Disord* 2005; 7: 67-81.
31. GUNN AJ, PARER JT, MALLARD EC et al. Cerebral histologic and electrocorticographic changes after asphyxia in fetal sheep. *Pediatr Res* 1992; 31: 486-491.
32. PEZZANI C, RADVANI-BOUVET MF, RELIER JP, MONOD N. Neonatal electroencephalography during the first 24 hours of life in full term newborn infants. *Neuropaediatrics* 1986; 17: 11-18.
33. PRESSLER RM, BOYLAN GB, MORTON M et al. Early serial EEG in hypoxic ischaemic encephalopathy. *Clin Neurophysiol* 2001; 112: 31-37.
34. PAINTER MJ, SCHER MS, STEIN AD et al. Phenobarbital compared with phenytoin for the treatment of neonatal seizures. *N Eng J Med* 1999; 341: 485-489.
35. GILMAN, JT. Rapid sequential phenobarbitone therapy of neonatal seizures. *Pediatrics* 1989; 83: 674-678.
36. BOYLAN GB, RENNIE JM, PRESSLER RM et al. Phenobarbitone, neonatal seizures and video-EEG. *Arch Dis Child* 2002; 86: F165-170.

37. SCHER M, ALVIN J, GAUS L et al. Uncoupling of EEG-clinical neonatal seizures after antiepileptic drug use. *Pediatric Neurology* 2003; 28: 277-280.
38. GLYKYS J, DZHALA VI, KUCHIBHOTLA KV et al. Differences in cortical versus subcortical GABAergic signaling: a candidate mechanism of electroclinical uncoupling of neonatal seizures. *Neuron* 2009; 63: 657-72.
39. SHETH RD, BUCKLEY DJ, GUTIERREZ AR et al. Midazolam in the treatment of refractory neonatal seizures. *Clin Neuropharmacol* 1996; 19: 165-170.
40. REY E, RADVANYI-BOUVET MF, BODIQU C et al. Intravenous lidocaine in the treatment of convulsions in the neonatal period: monitoring plasma levels. *Ther Drug Monitoring* 1990; 12: 316-320.
41. HELLSTROM-WESTAS L, WESTGREN U, ROSEN I, SVENNINGSEN NW Lidocaine for treatment of severe seizures in newborn infants. I. Clinical effects and cerebral electrical activity monitoring. *Acta Paediatr Scand* 1988; 77: 79-84.
42. BOYLAN GB, RENNIE JM, CHORLEY G et al. Second-line anticonvulsant treatment of neonatal seizures: a video-EEG monitoring study. *Neurology* 2004; 62(3): 486-488.
43. MALINGRE MM, Van ROOIJ LG, RADEMAKER CM et al. Development of an optimal lidocaine infusion strategy for neonatal seizures. *Eur J Pediatr* 2006; 165(9): 598-604.
44. BOOTH D, EVANS DJ. Anticonvulsants for neonates with seizures. *Cochrane Database Syst Rev* 2004; 18(4): CD004218.
45. RIVIELLO JJ. Drug Therapy for neonatal seizures: part 1. *NeoReviews* 2004; 5: 215-220.
46. RIVIELLO JJ. Drug Therapy for neonatal seizures: part 2. *NeoReviews* 2004; 5: 262-268.
47. BERGMAN I, PAINTER MJ, HIRSCH RP et al. Outcome in neonates with convulsions treated in ICU. *Ann Neurol* 1983; 14: 642-647.
48. SCHER MS, ASO K, BEGGARLY ME et al. Electrographic seizures in preterm and full term neonates: clinical correlates, associated brain lesions and risk for neurologic sequelae. *Pediatrics* 1993; 91: 128-134.
49. HOLMES GL, KHAZIPOV R, BEN-ARI Y. New concepts in neonatal seizures. *Neuroreport* 2002; 13:A3-A8.
50. CORNEJO BJ, MESCHES MH, COULTRAP S et al. A single episode of neonatal seizures permanently alters glutamatergic synapses. *Ann Neurol* 2007; 61(5): 411-426.
51. WASTERLAIN CG. Recurrent seizures in the developing brain are harmful. *Epilepsia* 1997; 38: 728-734.
52. WIRRELL EC, ARMSTRONG EA, OSMAN LD et al. Prolonged seizures exacerbate perinatal hypoxic-ischemic brain damage. *Pediatric Res* 2001; 50: 445-454.
53. BITTIGAU P, SIFRINGER M, GENZ K et al. Antiepileptic drugs and apoptotic neurodegeneration in the developing brain. *Proc Natl Acad Sci USA* 2002; 99(23): 15089-15094.
54. KIM JS, KONDRATYEV A, TOMITA Y, GALE K. Neurodevelopmental impact of antiepileptic drugs and seizures in the immature brain. *Epilepsia* 2007; 48 (Suppl 5): 19-26.