

Idiopathic generalised epilepsies

MICHAEL KOUTROUMANIDIS

St Thomas' Hospital, London

Introduction

The idiopathic generalised epilepsies (IGE) constitute roughly one-third of all epilepsies. Etymologically, the term 'idiopathic' comes from the Greek word 'idios', which simply means 'oneself'. An idiopathic syndrome therefore may be conceptualised as a disease unto itself, a *sui generis* condition. It follows that an idiopathic epilepsy syndrome:

- Consists only of recurrent epileptic seizures
- Is not associated with structural brain lesions on MRI or abnormal neurological symptoms and/or signs inter-ictally and implies normal neuropsychological status.

It should be also made clear that the term idiopathic is not synonymous with 'benign', as some subtypes such as juvenile myoclonic epilepsy (JME) are often life-long conditions, or with 'genetic', as not all genetic conditions are idiopathic, such as the progressive myoclonic epilepsies, or finally with 'unknown aetiology', as the genetic background of some subtypes such as JME and childhood absence epilepsy (CAE) has already been identified¹.

The term 'generalised' refers to the seizures 'in which the first clinical changes indicate initial involvement of both hemispheres... The ictal encephalographic patterns initially are bilateral'^{2,3}. This statement however is not entirely true. Video-EEG experience has taught us that typical absences (TA) may show an interhemispheric difference of 100–200 ms at their onset (without consistent side emphasis), and that some patients may show focal or lateralising ictal clinical features^{4,5}. Finally, at least 40% of patients with idiopathic generalised epilepsies (IGE) display non-localising focal discharges in the inter-ictal EEG (with or without generalised discharges)^{4,6}.

The IGEs comprise several sub-syndromes, characterised by all or some of the three seizure types – TA, myoclonic jerks and generalised tonic-clonic seizures (GTCS) – in different combinations and emphasis. These sub-syndromes usually have distinct electroclinical features and prognosis; some are life-long while others are age-related. However, accurate syndromic diagnosis may not be possible from the first presentation, and a number of patients with IGE may be difficult to classify.

The classification of IGE sub-syndromes over recent years has been controversial and a lively debate continues in view of the long-awaited new classification scheme of the ILAE⁷. There are two schools of thought: the 'lumpers', who hold that although IGE sub-syndromes can be recognised, their boundaries are indistinct, and that all forms of IGE fall into the same neurobiological continuum with genetic relationships^{8,9}; and the 'splitters', who take the view that precise syndromic classification provides a nosologic framework of

utmost importance for treatment and prognosis of an individual patient, and a sound basis for genetic and neurobiological research¹⁰⁻¹².

The Commission on Classification of the ILAE³ defined IGE as follows:

Idiopathic generalised epilepsies are forms of generalised epilepsies in which all seizures are initially generalised (absences, myoclonic jerks and generalised tonic-clonic seizures), with an EEG expression that is a generalised bilateral, synchronous, symmetrical discharge (such as is described in the seizure classification of the corresponding type). The patient usually has a normal inter-ictal state, without neurological or neuroradiologic signs. In general, inter-ictal EEGs show normal background activity and generalised discharges, such as spikes, polyspike spike-wave, and polyspike-waves ≥ 3 Hz. The discharges are increased by slow sleep. The various syndromes of idiopathic generalised epilepsies differ mainly in age of onset. No aetiology can be found other than a genetic predisposition towards these disorders.

The seizures in IGE

The seizures of IGE are typical absences (TA), myoclonic jerks and generalised tonic-clonic seizures (GTCS)^{2,3}. Of these, TA occupy a central position as they occur almost exclusively in the context of the IGEs², and are neurophysiologically and pharmacologically unique^{13,14}, which in turn makes their treatment different.

1. Typical absences

TA are brief, generalised epileptic seizures, characterised clinically by impairment of consciousness (absence) that occurs without warning and also ceases suddenly and without post-ictal symptoms, and electrographically by generalised 4–3 Hz spike and slow-wave discharge² that terminates without subsequent electrical flattening. Along these rather strict lines, TA tend to display a considerable clinical and EEG variability that may be syndrome-related.

Impairment of consciousness may range from mild to severe, and may occur either in isolation, or in association with other ictal manifestations, such as automatisms, autonomic signs, and regional (mouth or eyes) or widespread (head, limbs, and trunk) rhythmic or random myoclonia. Clinical subtypes of TA therefore include absences with impairment of consciousness only, with clonic, atonic, tonic, or autonomic components, and with automatisms^{2,15,16}. In turn, the accompanying EEG discharge may be very brief or long (usually between 3 and 30 seconds), continuous or fragmented, with regular or varying intradischarge frequency, may display spike or multiple spike components, and even show non-consistent side preponderance. It is usually faster and unstable in the opening phase (first second), becomes more regular and stable in the initial phase (next three seconds), and slows down towards the terminal phase (last three seconds). Background activity is normal, and inter-ictal fast, non-localising spikes may occur, usually over the frontal areas.

TA may occur spontaneously, and are typically provoked by hyperventilation, but also by other specific triggers, e.g. photic or pattern stimulation, video games, thinking, or even reading. They may be the sole or the predominant seizure type in individual patients, such as in CAE or juvenile absence epilepsy (JAE), or coexist with other generalised seizures, such as GTCS or myoclonic jerks, as in JME. Natural history may also vary: TA may remit with age or persist requiring continuous treatment; approximately 10–15% of adults with epilepsies have TA, often combined with other types of generalised seizures¹⁷⁻¹⁹.

A distinction should be made between typical and atypical absences. As opposed to TA, atypical absences² occur only in the context of mainly severe symptomatic or cryptogenic epilepsies of children with learning difficulties, who also suffer from frequent seizures of other types such as atonic, tonic, and myoclonic seizures. Clinically, onset and offset may not be as abrupt as in TA, and ictal changes of tone are usually more pronounced. The EEG features are also different: the ictal discharge is slower (< 2.5 Hz) and irregular, and may include other paroxysmal activity. Background activity is usually abnormal, and consistent focal abnormalities may exist.

2. Myoclonic seizures

Myoclonic seizures (MS) are shock-like, brief, irregular, arrhythmic and less often rhythmic, clonic twitching movements singular or repetitive^{2,3}. They may affect facial, limb, and neck or trunk muscles with varying force, amplitude and combinations. Their force may range from mild and inconspicuous movements of the affected muscle groups to violent movements of limbs and body that may make the patient fall on the ground, drop or throw things or kick in the air. Commonly, the same patients experience combinations of mild and violent jerks. MS may affect any muscle or group of muscles. They predominantly affect eyelids, facial and neck muscles, and the upper more than the lower limbs. MS of IGE occur mainly on awakening. Precipitating factors include sleep deprivation, fatigue, excitement or distress, and often photic stimulation.

In pure MS consciousness is not impaired and the patient is fully aware of them. However, myoclonic jerks are often a consistent ictal symptom of absence seizures^{20,21}. The EEG hallmark of MS are generalised bursts of polyspikes/polyspike-wave with variable side emphasis and anterior predominance.

Eliciting a clinical history of MS is not always straightforward. The answer to a direct question ‘Do you have jerks?’ is usually negative. Diagnostic yield improves by physically demonstrating myoclonic jerks, and by inquiring about morning clumsiness and tremors (‘Do you spill your morning tea?’ or ‘Do you drop things in the morning?’). Demonstrating that MS often relate to fatigue, alcohol indulgence and sleep deprivation is also essential. One has to bear in mind that MS may not be perfectly symmetrical and that occasionally they may be clearly lateralised, although without consistent side emphasis.

3. Generalised tonic-clonic seizures

GTCS in IGE are primary in the sense that they are generalised from onset as opposed to the secondary GTCS in focal epilepsies. The seizure itself is the same irrespective of epilepsy syndrome. The main difference is in the preceding and sometimes in the ensuing clinical and EEG phases. The GTCS in focal epilepsies are secondary to a cortical focus and may be preceded by subjective symptoms (aura) or signs that indicate a focal onset. Post-ictal lateralising electroclinical features (such as more depressed EEG activity over one hemisphere or asymmetry in muscle hypotonia) would also argue for a focal onset. Conversely, GTCS in IGE will occur without initial focal features, either out of the blue or after clusters of MS or TA, or absence status epilepticus that may warn patients of an impending convulsion. However, one has to bear in mind that rapid secondary generalisation may effectively conceal a focal or lateralising onset from a symptomatic focus, and conversely that GTCS in IGE may occasionally start with focal features such as head turning.

Though dramatic, GTCS do not bear any diagnostic significance. It is the minor seizures that provide the clues to diagnosis, investigative procedures and appropriate management. Patients often seek medical attention for the first time because of a GTCS. This is often erroneously considered as the ‘first seizure’ and is not treated or investigated. The truth is that the first GTCS in IGE is usually preceded for months or years by undiagnosed MS

and TA, and it is their recognition that should prompt suitable treatment. Conversely, patients may not have GTCS for years but this does not necessarily mean that they are 'seizure free'. Absences or myoclonic jerks may continue and treatment should be optimised instead of withdrawn.

The syndromes of IGE

Epilepsy syndromes, defined as clusters of symptoms or signs occurring consistently together, form the basis of the currently accepted classification of the epilepsies, and such a concept is practical for diagnosis, orientation of treatment and prognosis, and selection of appropriate investigations. A number of IGE syndromes feature in the current³ and the recently proposed⁷ classification systems of the ILAE, while others have not been recognised yet. In addition, there are patients with IGE who do not fit easily into recognisable syndromes.

The IGE syndromes currently recognised by the ILAE are shown in Table I. Benign neonatal familial convulsions, benign neonatal convulsions and benign myoclonic epilepsies in infancy are not dealt with here.

IGE syndromes not yet recognised by the Commission of the ILAE include eyelid myoclonia with absences (EMA), perioral myoclonia with absences (PMA), idiopathic generalised epilepsy with phantom absences, and stimulus-sensitive absence epilepsies.

Childhood absence epilepsy (CAE)^{12,20,22} is the archetypal syndrome of typical absence seizures, with onset usually before the age of ten years and a peak at 5–6 years. The prevalence of CAE is 10–12% for children with epilepsy younger than 16 years of age^{23,24}. As a rule, TA is the only seizure type at presentation and for the first active period of absences, but infrequent GTCS may occur in adolescence or adult life. TA occur frequently (tens or hundred per day), last for 4–30 seconds (usually around 10 seconds), and are associated with severe impairment of consciousness.

Clinically, there is abrupt and severe loss of awareness, and complete unresponsiveness. The eyes spontaneously open and stare or move slowly, and all voluntary activity stops within the first three seconds of the seizure. Random eyelid blinking (usually not sustained) may occur, and mild, mainly orofacial, automatisms are frequent¹⁵. There may also be a transient impairment of postural tone, resulting in the head, limbs or trunk dropping, and sometimes an increase in tone that leads to retropulsion. Ictal clinical symptoms and signs inconsistent with CAE include mild impairment of consciousness, pronounced and rhythmical myoclonus either regional (eyelid or perioral) or massive limb jerking, and single or arrhythmic myoclonic jerks of the head, trunk, or limbs. The occurrence of other generalised seizures, such as GTCS, or myoclonic jerks, prior to or during the active period of the absences, and sensitivity to photic or other sensory triggers is also thought to be incompatible with CAE^{12,20,22}. The background EEG is normal with frequent rhythmic posterior delta activity. Ictal discharges consist of generalised high amplitude 2.5–4 Hz spike-wave and are longer than 4 seconds.

Prognosis and evolution of CAE depends on the applied diagnostic criteria. Delineated as above, CAE has an excellent prognosis; TA are responsive to treatment and remission occurs in more than 80–90% of children before the age of 12 years. However prognosis becomes variable when one includes in CAE every child with onset of absences before the age of ten years. GTCS occur in perhaps more than one-third of patients, either during adolescence²⁵ or in the third decade of life²⁶, and some patients may develop JME^{1,27}. TA in these patients may persist, improve or disappear. Most of the available evidence on the

Table I. Idiopathic generalised epilepsies as perceived by the relevant Committees of the ILAE.

Commission of the ILAE (1989)

Idiopathic generalised epilepsies

Benign neonatal familial convulsions

Rare, dominantly inherited disorders manifesting mostly on the second and third days of life, with clonic or apnoeic seizures and no specific EEG criteria. History and investigations reveal no aetiological factors. About 14% of patients develop epilepsy later.

Benign neonatal convulsions

Very frequently repeated clonic or apnoeic seizures occurring about the fifth day of life, without known aetiology or concomitant metabolic disturbance. Inter-ictal EEG often shows alternating sharp theta waves. No recurrence of seizures. Psychomotor development not affected.

Benign myoclonic epilepsy in infancy

Characterised by brief bursts of generalised myoclonus associated with generalised spike-waves occurring during the first or second year of life in otherwise normal children who often have a family history of convulsions or epilepsy. Generalised tonic-clonic seizures may occur during adolescence.

Childhood absence epilepsy (pyknolepsy)

Juvenile absence epilepsy

Juvenile myoclonic epilepsy (impulsive petit mal)

Epilepsy with generalised tonic-clonic seizures on awakening

Epilepsies with seizures precipitated by specific modes of activation

Most of the photosensitive epilepsies belong to the group of idiopathic generalised epilepsies.

Other generalised epilepsies not defined above

ILAE Task Force on Classification (2001)

Idiopathic generalised epilepsies

Benign myoclonic epilepsy in infancy

Epilepsy with myoclonic astatic seizures

Childhood absence epilepsy

Epilepsy with myoclonic absences

Idiopathic generalised epilepsies with variable phenotypes

- *Juvenile absence epilepsy*
- *Juvenile myoclonic epilepsy*
- *Epilepsy with generalised tonic-clonic seizures only*

Generalised epilepsies with febrile seizures plus (to consider)

prognosis of CAE is inconclusive, and certainly one could argue that such patients may not have CAE but another form of IGE (JAE or JME).

Juvenile absence epilepsy (JAE)^{20,28,29} is mainly characterised by TA that are similar to those in CAE, but much less frequent and probably not as severe. Age at onset of TA is 7–16 years with a peak at 10–12 years. Random and infrequent myoclonic jerks^{15,30}, as well as infrequent GTCS, occur in most of the patients. One-fifth of patients also suffer attacks of absence status epilepticus³¹.

TA may be frequent, sometimes daily. The interrupted ongoing voluntary activity may be partly restored during the ictus, and clinical recovery may occur prior to the termination of the EEG ictal discharge. Automatisms are frequent, usually occurring 6–10 seconds after the onset of the discharge. The combination of peri-oral or hand automatisms and staring may lead to misdiagnosis of such TA for complex partial (limbic) seizure and vice versa⁶. JAE is usually a life-long disorder, but absences tend to become less severe with age. The ictal EEG is not fundamentally different than in CAE. Similarly to the latter, ictal features such as mild impairment of consciousness and brief ictal discharges (less than 4 seconds), eyelid or perioral myoclonus, rhythmic limb jerking, and single or arrhythmic myoclonic jerks are thought to be exclusion criteria for JAE. As with CAE, 80% or more of the patients become seizure free with appropriate treatment, but the risk of relapse following discontinuation of medication is not clearly defined.

*Juvenile myoclonic epilepsy (JME) (Janz syndrome)*³² is characterised by myoclonic jerks on awakening, GTCS, and TA, with the latter occurring in more than one-third of the patients^{28,33,34}. However, TA are not the predominant seizure type, and are usually very mild and simple (with no automatisms or localised limb jerks). Seizure precipitating factors include sleep deprivation and fatigue, alcohol, and mental and psychological arousal, and up to 40% of patients are photosensitive³³. TA, when present, begin between the ages of five and 16 years, MS usually follow sooner or later, with the GTCS being the last to appear in most cases. An adult form of this syndrome has also been described³⁵. All seizure types are probably life-long, although TA may become less severe with age, and MS and GTCS commonly improve after the fourth decade of life. Prevalence of JME alone is around 9% of adults with seizures³⁴, and both sexes are equally affected. Generalised spike-wave discharges at 3–6 Hz have an unstable intradischarge frequency with fragmentations and multiple spikes.

Myoclonic absence epilepsy (MAE) is a rare generalised cryptogenic or symptomatic absence epilepsy, although an idiopathic form may also exist. TA occur many times a day and constitute the predominant seizure type. Ictally, severe bilateral rhythmical clonic jerks are often associated with a tonic contraction, and some awareness is maintained. Age of onset is around seven years, and there is a male preponderance. Prognosis is not good because of resistance to therapy, mental deterioration, and possible evolution to other types of epilepsy such as Lennox-Gastaut syndrome^{36,37}.

Epilepsy with GTCS on awakening. The term denotes an idiopathic propensity to mainly or exclusively GTCS that occur mostly within the first two hours after awakening from sleep^{3,38,39}. They may also occur when the patient is awake at times of relaxation and leisure. Age at onset is mainly in the mid-teens but may start earlier or much later. Sleep deprivation, fatigue and excessive alcohol consumption are main precipitating factors. GTCS tend to increase in frequency with age, and may become unpredictable occurring also during sleep and alert stages. Avoidance of precipitating factors and adjustment of lifestyle are essential for the best management of these patients.

There is a considerable overlap with other IGEs that also manifest a similar circadian distribution and precipitating factors. Idiopathic epilepsy with GTCS on awakening³ is no longer recognised as a separate syndrome⁷. Instead, this is now rightly considered as part of ‘IGE with GTCS only’, referring to all patients with GTCS only, irrespective of circadian distribution. There are no other discernible clinical seizures though video-EEG may often demonstrate ‘phantom absences’.

The following syndromes are not recognised by the ILAE:

eyelid myoclonia with absences (EMA). TA are frequent, typically associated with marked, rhythmic, and fast jerks of the eyelids, often with jerky upward deviation of the eyeballs and retropulsion of the head. Absences are brief (3–6 seconds) and occur mainly after eye closure. GTCS and random myoclonic jerks of the limbs may occur infrequently, most likely after sleep deprivation, fatigue, and alcohol intake. Marked photosensitivity is the rule but declines with age. EMA usually starts in early childhood but may be resistant to treatment. The ictal EEG manifestations consist mainly of generalised polyspikes and slow-waves at 3–6 Hz^{40,41}. Patients practising self-induction should be differentiated from pure EMA and treated accordingly.

Perioral myoclonia with absences (PMA). Here, TA are also frequent and usually brief, associated with a variable impairment of consciousness and rhythmic myoclonus of the perioral facial or masticatory muscles. Clusters of absences or absence status occur commonly, and may precede GTCS. The latter are not frequent. PMA starts in childhood or early adolescence and TA and GTCS may be resistant to medication. Ictal EEG discharges are often irregular, and consist of rhythmic multiple spike-waves and slow-waves at 3–4 Hz. Photosensitivity is not encountered^{42,43}.

Idiopathic generalised epilepsy with phantom absences. The term ‘phantom absence’ denotes simple TA, which are so mild that they are inconspicuous to the patient and imperceptible to the observer. This syndrome also includes (usually late onset) GTCS, and absence status in 50% of the patients. TA are disclosed by video-EEG (prompted by the GTCS) and breath counting or other cognitive testing during hyperventilation, when brief (up to 4 seconds) 3–4 Hz spike or multiple spike-wave discharges interfere with cognitive performance¹⁸.

Absences with specific modes of precipitation (photic, pattern, video-games, emotional upset, intense thinking, and reading) and their underlying mechanisms have been recently reviewed⁴⁴. Photosensitivity is estimated to occur in approximately one-fifth of patients with onset of absences in childhood or adolescence and it is associated with unfavourable prognosis. Apart from all patients with EMA and up to 30–40% of those with JME who are photosensitive, others with spontaneous and photically provoked absences and GTCS may belong to various syndromes not yet identified.

Absences in symptomatic or cryptogenic (probably symptomatic) focal epilepsies have been documented only occasionally and in specific topographic and pathologic substrates, notably in patients with seizures arising from the medial intermediate frontal area⁴⁵, and in others with cerebral cortical dysgenesis and involvement of the archicortex⁴⁶. In both instances, brief impairment of cognition associated with 3 Hz spike-wave EEG paroxysms would probably qualify these seizures as TA, but these absence-like events usually coexist with complex partial seizures with or without secondary generalisation, and require completely different management. TA may occasionally arise as a consequence of a known disorder of the central nervous system⁴⁷, but in most cases an aetiological link is not proven, and it is likely that they are coincidental. Finally, the co-

existence of IGE with TA and symptomatic partial epilepsy in the same patient is seemingly rare although probably underdiagnosed⁶.

Diagnosis and differentials

Diagnosis of TA in children with severe ictal impairment of consciousness is relatively easy. Their brief duration with abrupt onset and termination, high daily frequency, and nearly invariable provocation with hyperventilation makes them one of the easiest types of seizures to recognise. The child with suspected TA should be asked to overbreathe for three minutes, counting his or her breaths while standing with hands extended in front; hyperventilation will provoke an absence in more than 90% of those who suffer. We recommend that this test should also be undertaken in suspected adults, in whom TAs are usually mild and may be missed. Misinterpretation of TA for partial seizures (focal motor in the case of regional asymmetric ictal myoclonic components, or complex partial – limbic – when ictal automatisms, such as perioral, swallowing, fumbling are present) may seriously affect management and treatment. The basic clinical criteria for differentiating TA from complex partial seizures are given in Table II. The clinical approach needs to be complemented by (preferably video) EEG studies, ideally prior to commencing treatment. An EEG would confirm the diagnosis of TA in more than 90% of these untreated children with ictal recordings mainly during hyperventilation. If not, the diagnosis of absences should be questioned⁴⁸. In addition, ictal video-EEG documentation may reveal features favouring a specific epileptic syndrome and assist in determining long-term prognosis and management. The fundamental EEG differences between TA and complex partial seizures are also shown in Table II.

Diagnosis of other co-existent seizure types, and definition, if possible, of the electroclinical syndrome as outlined in the previous section is the final diagnostic step before initiating treatment. Symptomatic absences in non-lesional frontal lobe epilepsy are often impossible to distinguish, especially in the absence of partial seizures⁴⁵. Cerebral cortical dysgenesis is usually detectable on brain MRI⁴⁶. Such symptomatic/cryptogenic absences are very rare. Finally, TA in IGE can be easily differentiated from atypical absences that occur only in the context of mainly severe symptomatic or cryptogenic epilepsies in children with learning difficulties and frequent seizures of other types, such as atonic, tonic, and myoclonic seizures.

Treatment

General principles

Prognosis is syndrome-related. For instance, childhood absence epilepsy is a relatively benign syndrome, which usually remits within 2–5 years from onset. In all other IGE syndromes there is probably a life-long liability to TA, myoclonic jerks, and GTCS. Poor initial response to treatment^{49,50} and photosensitivity⁴⁹ may be of adverse prognostic value for long-term remission of seizures. Repeat EEG is particularly useful in monitoring the response to treatment as there is a very close correlation between control of clinical absences and electrographic abnormalities^{51,52}; such a relationship does not exist in other generalised seizures (tonic-clonic or myoclonic), or in partial epilepsies.

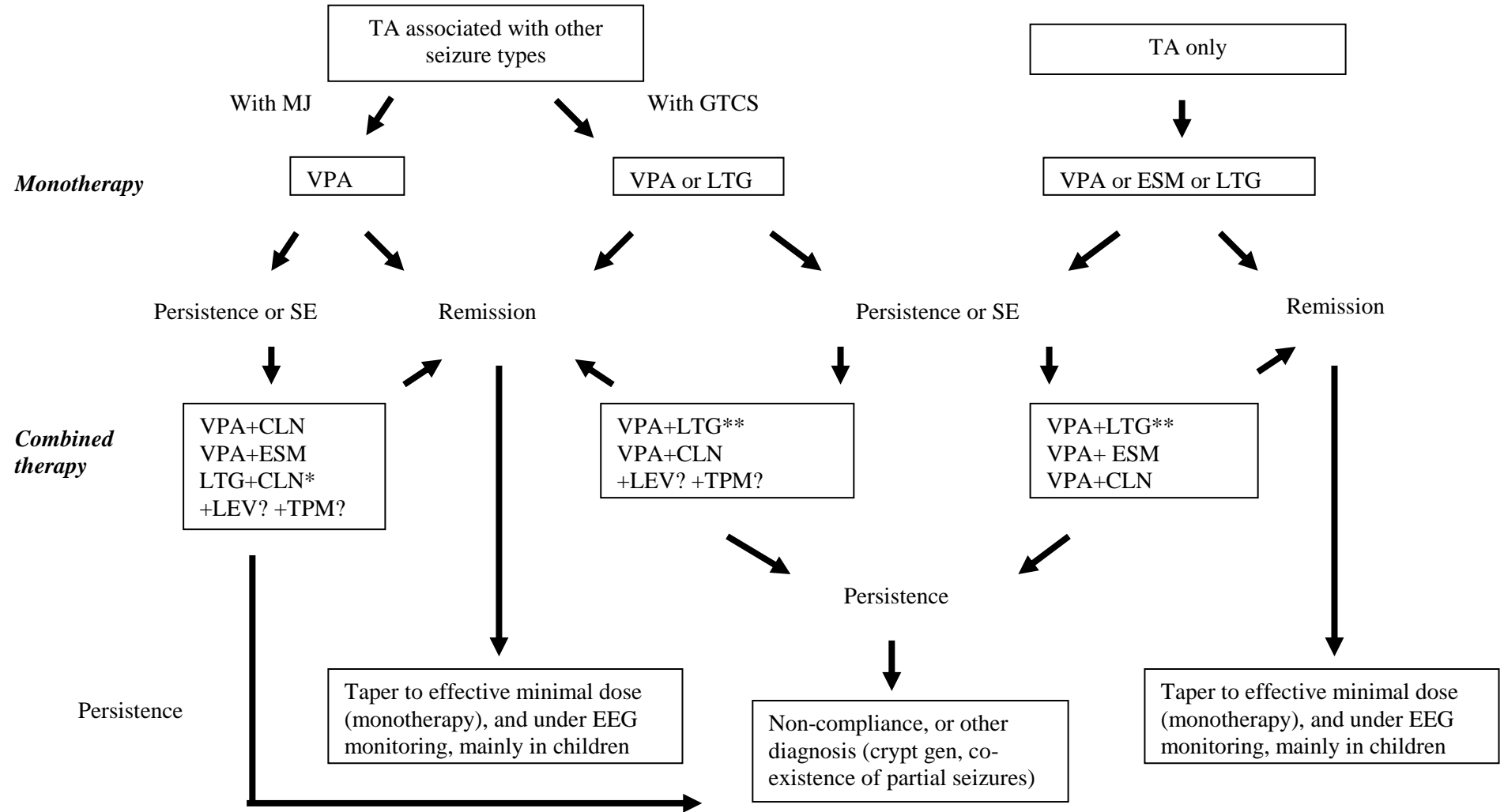
Planning of management and appropriate advice and counselling is therefore possible once a confident syndromic diagnosis has been established, or at least the question of possible photosensitivity or other reflex activation, and the co-existence of myoclonic jerks, GTCS or both has been answered satisfactorily. Currently, sodium valproate, ethosuximide and lamotrigine, alone or in combination, are the only first-line agents for TA. Choice between them depends on other co-existent generalised seizures, and –

Table II. Differential diagnosis between typical absences and limbic temporal lobe seizures.

	Limbic CPS (mesial TLE)	Typical absences (IGE)
History		
Febrile convulsions	Frequent; usually multiple, prolonged or complicated	Frequent but rarely prolonged or complicated
Family history	Usually of febrile convulsions; rarely of partial seizures (familial TLE)	Positive in up to 40% of patients
Onset	Usually within the second half of the first decade	Usually syndrome-related
Course (natural history)	Often bi-phasic	Continuous*
Diurnal variation	Non-specific	Usually in the morning/after awakening
Ictal clinical features		
Aura	Frequent	Never
Precipitation by HV	Exceptional	As a rule
Precipitation by IPS	Exceptional	Typical (but usually syndrome-related, as in JME and EMA)
Lapse of awareness	Usually profound	Varies (often syndrome-related)
Automatisms	Almost invariably, often involving trunk and legs. Ipsilateral to the focus automatisms associated with contralateral dystonic posture may occur in 40% of patients late in the seizure	Up to about 2/3 of seizures, rarely involving trunk or legs
Clonic components	Rare; unilateral – if present – and late in the ictal sequence	Frequent, bilateral, mainly restricted to the eyelids or mouth
Reactive automatisms	Frequent	Only during absence status
> 1 min duration	As a rule	Exceptional
Non-convulsive status	Exceptional	Well recognised feature
Post-ictal symptoms/signs	Invariably confusion, recent memory deficit, dysphasia if onset from the dominant side. Relatively rapid clearing may occasionally occur	Never
Inter-ictal EEG (scalp)	Unilateral or bilateral independent temporal spikes, or regional slow activity. Brief bilateral and synchronous bursts of spike-wave may occur in the context of obvious or occult secondary bilateral synchrony	Generalised spike and wave discharges at 4–2.5 Hz. Focal spikes may occur in up to 30–40% of traces but they show frontal topography, and do not disturb background activity
Ictal EEG (scalp)	Focal onset	Generalised onset
Neurological examination	Normal (a degree of facial asymmetry may be present)	Normal
Neuropsychology	Often discrepancy between Verbal IQ and Performance IQ, material specific memory deficits	Normal
Brain MRI	Usually mesial temporal atrophy	Normal

HV: hyperventilation; IPS: intermittent photic stimulation; *: in CAE GTCS may occur in up to 1/3 of patients after the remittance of the typical absences

Table III. Tree diagram of the treatment of TA according to syndrome-related co-existence of other seizure types.



MJ: myoclonic seizures; GTCS: generalised tonic-clonic; VA: sodium valproate; ESM: ethosuximide; LTG: lamotrigine; CLN: clonazepam; LEV: levetiracetam; TPM: topiramate; SE: side effects; *: in VA-resistant or -sensitive patients (e.g. women), and probably when the myoclonic component is not severe; **: titrate the dose of LTG according to clinical response; low to moderate doses are usually effective; ?: effectiveness as adjunctive treatment remains to be proven

obviously – adverse reactions. Table III presents the proposed steps in the therapeutic process that targets TA in different clinical patterns.

Monotherapy

Satisfactory seizure control with monotherapy is the desired aim in the treatment of the epilepsies, and naturally IGE is not an exception. Any of the three first-line drugs can be initiated and lack of effectiveness should not be assumed before ensuring that the maximum tolerated dose has been achieved. If monotherapy with a particular agent finally fails, or unacceptable adverse reactions appear, substitution with one of the other drugs is the next step.

Sodium valproate is the most effective drug in the treatment of all types of generalised seizures with 75% of patients becoming seizure-free on monotherapy. It is used by most physicians not only as first choice for monotherapy irrespective of absence syndrome, but also as a solid basis for adjunctive therapy^{53,54} (Table III). In addition, sodium valproate prevents the recurrence of absence status⁵⁵, is effective in myoclonic absences⁵⁶, which are particularly difficult to treat, and can abolish photosensitivity. There are anecdotal reports where children may not respond to the syrup form, despite adequate levels, but do so with sodium valproate tablets. Common adverse effects include nausea, vomiting, dyspepsia, gain in bodyweight, tremor, transient hair loss and haematological abnormalities. The latter, even when highly clinically significant, can be reversible following dosage reduction; discontinuation is rarely required⁵⁷. Behavioural and cognitive abnormalities, and acute liver necrosis⁵⁸ and pancreatitis, that may be fatal and more likely to occur in children on polypharmacy, are rare. However, the main factors that hamper its use, mainly in women⁵⁹, include an estimated risk of 1– 2% for neural tube defects, predominantly spina bifida aperta, in pregnancy (background population risk 0.2–0.5%), which may increase when the drug is combined with benzodiazepines⁶⁰, the as yet unresolved question of polycystic ovarian syndrome^{61–63} and other endocrine side effects, and hair loss. Occasional worsening of TA with sodium valproate has been reported⁶⁴.

Ethosuximide is effective in TA, nearly as much as sodium valproate⁶⁵, but does not protect against GTCS and myoclonic seizures (Table III). Therefore, while ethosuximide might be a reasonable choice in a young child with CAE, it is not recommended as a first-line choice in an older child with possible JAE (due to the much higher chance of developing CTCS), and in JME. Common adverse effects are usually dose-related and include gastrointestinal disturbances, anorexia, weight loss, drowsiness, photophobia and headache. Behaviour and psychotic disturbances may occur. Aplastic anaemia, Stevens-Johnson syndrome, renal and hepatic impairment are rare but life threatening.

Lamotrigine controls TA and GTCS^{66,67}, but its effect on MS is unpredictable (Table III), and exacerbation of JME has been reported with lamotrigine⁶⁸. Lamotrigine monotherapy may be tried in women, particularly those that may be more vulnerable to side effects of sodium valproate. Dose escalation should be gradual: in adults and children over 12 years initial dose is 25 mg daily for two weeks, followed by 50 mg daily for two weeks. Maintenance dose is 100–200 mg/day in two divided doses, but can be increased to 400 mg per day in the absence of a satisfactory response. In younger children, and in accordance with the recommendations regarding add-on lamotrigine in this age group, the initial dose is 0.3 mg/kg bodyweight/day daily for two weeks, followed by 0.6 mg/kg/day daily for two weeks. Maximum escalation should not exceed 0.6 mg/kg every 1–2 weeks until optimal response. Maintenance dose usually ranges between 2.5 and 7 mg/kg/day given in one or two divided doses, but can reach 10 mg/kg/day if lamotrigine is not combined with sodium valproate. This gradual initial dose titration reduces the risk of allergic skin rash, which is higher when the drug is prescribed in combination sodium valproate which inhibits lamotrigine metabolism. Skin rash occurs in

approximately 10% of patients, usually in the first eight weeks, and prompts discontinuation of the drug. Serious rashes leading to hospitalisation, including Stevens-Johnson syndrome and hypersensitivity syndrome, occur in approximately one in 300 adults and one in 100 children^{67,69}. Other common side effects include headache, nausea, diplopia, dizziness, ataxia and tremor.

Combined therapy and second-line anti-absence drugs

Selection of drug combination is again based on the clinical pattern principle.

Lamotrigine. More than half of patients with valproate-resistant absences may become seizure free with add-on lamotrigine⁷⁰. This combination is also highly effective with regard to myoclonic seizures and GTCS (Table III). The effect is probably mediated through inhibition of lamotrigine metabolism by sodium valproate, and can be best achieved by escalating the dose of lamotrigine according to clinical response and not to the recommended upper 'therapeutic' doses⁷⁰. The drug has been used in children with myoclonic absences with good results³⁷. Anecdotal evidence suggests that a favourable response on substantial dose of sodium valproate combined with a low to moderate dose of lamotrigine may be lost if lamotrigine is further increased and substitution of sodium valproate is attempted. This combination may augment the risk for allergic skin reaction, and may rarely provoke other adverse immune responses⁷¹.

Ethosuximide. The addition of sodium valproate to ethosuximide may double serum concentration of the latter with concomitant toxicity⁷². Conversely, the addition of ethosuximide may reduce serum level concentration of sodium valproate. Bearing this interaction in mind, the combination of sodium valproate and ethosuximide may be helpful in managing refractory absences⁶⁵, and is probably the first-line treatment of myoclonic absences³⁶.

Clonazepam is considered the most effective anti-absence benzodiazepine and the most powerful drug against myoclonic jerks, with a good effect on GTCS^{73,74}. It may also be effective in photosensitive epilepsy⁷⁵. However, because of its potential to cause sedation and the problem of tolerance⁷⁶, it is usually prescribed as a second-line adjunctive therapy (Table III). Other adverse effects include fatigue and disturbance of coordination and, less commonly, agitation, confusion and aggressiveness. It is also useful to remember that its combination with sodium valproate during pregnancy may amplify the risk for teratogenicity⁶⁰. Rapid discontinuation should be avoided.

Acetazolamide has a clear anti-absence effect⁷⁷, and may also be useful in JME⁷⁸. Tolerance frequently develops but a period of withdrawal may restore its efficacy. Renal calculi are consequent to its carbonic anhydrase activity and together with rare but severe serious idiosyncratic reactions associated with sulfonamides (rash, aplastic anaemia, Stevens-Johnson syndrome) limit its use as an adjunctive treatment.

Levetiracetam can be effective as monotherapy in JME and other IGE sub-syndromes, and can suppress photosensitivity in combination or monotherapy^{79,80}.

Contraindicated AEDs

Antiepileptic drugs (AEDs) may aggravate pre-existing seizures or induce new seizure types, and such an effect may be either idiosyncratic or syndrome/seizure-related. Factors that hamper the identification of such AEDs include incorrect syndromic and seizure diagnosis, the natural fluctuation of seizure frequency and severity, and the fact that most drug trials are not based on a syndrome and age-specific approach, nor are they designed to

detect seizure worsening. Inevitably, most of the existing information on seizure aggravation relies on clinical observations on small series and case studies, and for some drugs such evidence is more convincing than for others. Knowing the drugs that can aggravate idiopathic generalised epilepsies with absences is particularly important as the vast majority have a favourable prognosis.

*Carbamazepine*⁸¹, *vigabatrin*⁸², *tiagabine*⁸³ and *gabapentin*⁸⁴ are contra-indicated in the treatment of TA irrespective of cause and severity. However, carbamazepine may be helpful in controlling GTCS⁸⁴. As GABAergic substances, vigabatrin, tiagabine and gabapentin are associated with induction of absence seizures and absence status epilepticus^{82,85}. The role of *phenytoin* is less clear, and perhaps less aggravating; therapeutic concentrations of phenytoin (and carbamazepine) exacerbate idiopathic generalised epilepsies, particularly those associated with TA, and may induce valproate and benzodiazepine-resistant absence status⁸⁶. These observations are echoed by a well-documented case report of six-week absence status that improved upon discontinuation of phenytoin⁸⁷. On the other hand, it is a common experience (shared also by ourselves) that seizure relapse may occur in patients with well-controlled idiopathic generalised epilepsy on chronic treatment with phenytoin (as part of a combination, usually with sodium valproate), when discontinuation or substitution of this drug is attempted.

A final note is reserved for the apparently unusual, although probably underdiagnosed, coexistence of IGE and symptomatic focal (temporal lobe) epilepsy, where considerations determining choice of medical therapy may be contradictory⁶. Determination of the most troublesome seizure type (usually these are the partial seizures with or without secondary generalisation) is clearly the primary diagnostic aim, and is based on clinical and inter-ictal/ictal EEG criteria (Table I). Drugs that may have adverse effects on 'primary' generalised seizures such as carbamazepine, vigabatrin and tiagabine should be used with caution and under close monitoring only if absolutely necessary, while those with a broad spectrum of antiepileptic effects such as sodium valproate or lamotrigine are more appropriate⁶.

Conclusion

Optimal management of absence epilepsies, including selection of the appropriate anti-absence drug (and avoidance of the contraindicated ones), advice on lifestyle restrictions, long-term planning of treatment, and definition of the likely outcome, relies on the diagnosis not only of absence seizures but also of possible co-existent myoclonic seizures, or GTCS, or both. As both response to treatment and long-term prognosis are largely syndrome-related, it is clinically important to make as precise a syndromic diagnosis as possible, or *at least attempt to form an initial working hypothesis*. This is because the diagnosis may not be apparent at first presentation, and close clinical and electroencephalographic follow-up may be necessary to complete the final diagnostic jigsaw. For example, a child with newly diagnosed TA does not necessarily have CAE; other generalised seizures (myoclonic jerks or GTCS or both) may subsequently appear, and suggest alternative diagnoses such as JAE or JME, forecasting a different outcome. It is also important to remember that not all generalised epilepsies with absences can fit into the syndromes of IGE recognised by the ILAE. Treatment-wise however, one can still work successfully along the lines of the tree diagram (Table III), taking into account the type of the associated clinical seizures and their relative preponderance in terms of frequency and severity.

Recognition of possible triggering factors is also essential for appropriate management. Photosensitivity is the most important precipitant of seizures in IGE, and its presence in a child with both spontaneous and photically induced absences would dictate the use of

sodium valproate as first choice and at full therapeutic doses, with clonazepam as a second-line drug. On the other hand, if only photically-induced absences and other generalised seizures occur, simple avoidance of stimulus may be sufficient, although in some patients the addition of a small protective dose of sodium valproate may be necessary.

The therapeutic response should be monitored with successive EEG studies. In children the evidence from school is also essential. As in other epilepsies, good compliance must be consistently monitored.

References

1. DELGADO-ESCUETA AV, MEDINA MT, SERRATOSA JM et al. Mapping and positional cloning of common idiopathic generalized epilepsies: juvenile myoclonus epilepsy and childhood absence epilepsy. *Adv Neurol* 1999; 79:351–374
2. Commission of Classification and Terminology of the International League Against Epilepsy. Proposal for revised clinical and electroencephalographic classification of epileptic seizures. *Epilepsia* 1981; 22:489–501
3. Commission on Classification and Terminology of the International League Against Epilepsy. Proposal for revised classification of epilepsies and epileptic syndromes. *Epilepsia* 1989; 30:389–399
4. LANCMAN ME, ASCONAPE JJ, GOLIMSTOK A. Circling seizures in a case of juvenile myoclonic epilepsy. *Epilepsia* 1994; 35:317–318
5. LEUTMEZER F, LURGER S, BAUMGARTNER C. Focal features in patients with idiopathic generalized epilepsy. *Epilepsy Res* 2002; 50:293–300
6. KOUTROUMANIDIS M, HENNESSY MJ, ELWES RD et al. Coexistence of temporal lobe and idiopathic generalized epilepsies. *Neurology* 1999; 53:490–495
7. ENGEL J Jr. A proposed diagnostic scheme for people with epileptic seizures and with epilepsy: Report of the ILAE Task Force on Classification and Terminology. *Epilepsia* 2001; 42:796–803
8. BERKOVIC SF, ANDERMANN F, ANDERMANN E et al. Concepts of absence epilepsies: discrete syndromes or biological continuum? *Neurology* 1987; 37:993–1000
9. ANDERMANN F, BERKOVIC SF. Idiopathic generalized epilepsy with generalised and other seizures in adolescence. *Epilepsia* 2001; 42:317–320
10. MALAFOSSE A, GENTON P, HIRSCH E et al. Idiopathic generalised epilepsies. London: John Libbey & Company Ltd, 1994
11. PANAYIOTOPOULOS CP. Treatment of typical absence seizures and related epileptic syndromes. *Paediatr Drugs* 2001; 3:379–403
12. LOISEAU P, PANAYIOTOPOULOS CP, HIRSCH E. Childhood absence epilepsy and related syndromes. In: Roger J, Bureau M, Dravet C et al, eds. *Epileptic syndromes in infancy, childhood and adolescence* (3rd edn). 3rd ed. London: John Libbey & Co Ltd, 2002: 285–304
13. MARESCAUX C, VERGNES M. Animal models of absence seizures and absence epilepsies. In: Duncan JS, Panayiotopoulos CP, eds. *Typical absences and related epileptic syndromes*. London: Churchill Communications Europe, 1995: 8–18
14. FUTATSUGI Y, RIVIELLO JJ Jr. Mechanisms of generalized absence epilepsy. [Review] [29 refs]. *Brain Dev* 1998; 20:75–79
15. PANAYIOTOPOULOS CP, OBEID T, WAHEED G. Differentiation of typical absence seizures in epileptic syndromes. A video EEG study of 224 seizures in 20 patients. *Brain* 1989; 112:1039–1056
16. PENRY JK, PORTER RJ, DREIFUSS RE. Simultaneous recording of absence seizures with video tape and electroencephalography. A study of 374 seizures in 48 patients. *Brain* 1975; 98:427–440
17. PANAYIOTOPOULOS CP, GIANNAKODIMOS S, CHRONI E. Typical absences in adults. In: Duncan JS, Panayiotopoulos CP, eds. *Typical absences and related epileptic syndromes*. London: Churchill Communications Europe, 1995: 289–299
18. PANAYIOTOPOULOS CP, KOUTROUMANIDIS M, GIANNAKODIMOS S et al. Idiopathic generalised epilepsy in adults manifested by phantom absences, generalised tonic-clonic seizures, and frequent absence status [see comments]. *J Neurol Neurosurg Psychiatr* 1997; 63:622–627
19. MICHELUCCI R, RUBBOLI G, PASSARELLI D et al. Electroclinical features of idiopathic generalised epilepsy with persisting absences in adult life. *J Neurol Neurosurg Psychiatry* 1996; 61:471–477
20. PANAYIOTOPOULOS CP. Absence epilepsies. In: Engel JJ, Pedley TA, eds. *Epilepsy: A comprehensive Textbook*. Vol. III. Philadelphia: Lippincott-Raven Publishers, 1997: 2327–346
21. PANAYIOTOPOULOS CP. Typical absence seizures. In: Gilman S, ed. *Medlink Neurology 2002 ed*. San Diego SA: Arbor Publishing Corp, 2002
22. HIRSCH E, MARESCAUX C. What are the relevant criteria for a better classification of epileptic syndromes with typical absences? In: Malafosse A, Genton P, Hirsch E et al, eds. *Idiopathic generalised epilepsies*. London: John Libbey & Company Ltd, 1994: 87–93
23. CALLENBACH PM, GEERTS AT, ARTS WF et al. Familial occurrence of epilepsy in children with newly diagnosed multiple seizures: Dutch Study of Epilepsy in Childhood. *Epilepsia* 1998; 39:331–336

24. BERG AT, LEVY SR, TESTA FM et al. Classification of childhood epilepsy syndromes in newly diagnosed epilepsy: interrater agreement and reasons for disagreement. *Epilepsia* 1999; 40:439–444
25. DIETERICH E, BAIER WK, DOOSE H et al. Longterm follow-up of childhood epilepsy with absences. I. Epilepsy with absences at onset. *Neuropediatrics* 1985; 16:149–154
26. GASTAUT H, ZIFKIN BG, MARIANI E et al. The long-term course of primary generalized epilepsy with persisting absences. *Neurology* 1986; 36:1021–1028
27. WIRRELL EC, CAMFIELD CS, CAMFIELD PR et al. Long-term prognosis of typical childhood absence epilepsy: remission or progression to juvenile myoclonic epilepsy. *Neurology* 1996; 47:912–918
28. JANZ D. The idiopathic generalized epilepsies of adolescence with childhood and juvenile age of onset. *Epilepsia* 1997; 38:4–11
29. WOLF P. Juvenile absence epilepsy. In: Gilman S, ed. *Medlink Neurology 2002* ed. San Diego SA: Arbor Publishing Corp, 2002
30. WOLF P, INOUE Y. Therapeutic response of absence seizures in patients of an epilepsy clinic for adolescents and adults. *J Neurol* 1984; 231:225–229
31. AGATHONIKOU A, PANAYIOTOPOULOS CP, GIANNAKODIMOS S et al. Typical absence status in adults: diagnostic and syndromic considerations. *Epilepsia* 1998; 39:1265–1276
32. JANZ D, CHRISTIAN W. Impulsiv-Petit mal. *Zeitschr Nervenheilk* 1957; 176:346–386
33. PANAYIOTOPOULOS CP, OBEID T, TAHAN AR. Juvenile myoclonic epilepsy: a 5-year prospective study. *Epilepsia* 1994; 35:285–296
34. GRUNEWALD RA, PANAYIOTOPOULOS CP. Juvenile myoclonic epilepsy. *Arch Neurol* 1993; 50:594–598
35. GILLIAM F, STEINHOFF BJ, BITTERMANN HJ et al. Adult myoclonic epilepsy: a distinct syndrome of idiopathic generalized epilepsy. *Neurology* 2000; 55:1030–1033
36. TASSINARI CA, MICHELUCCI R, RUBBOLI G et al. Myoclonic absence epilepsy. In: Duncan JS, Panayiotopoulos CP, eds. *Typical absences and related epileptic syndromes*. London: Churchill Communications Europe, 1995: 187–195
37. MANONMANI V, WALLACE SJ. Epilepsy with myoclonic absences. *Arch Dis Child* 1994; 70:288–290
38. JANZ D. Pitfalls in the diagnosis of grand mal on awakening. In: Wolf P, ed. *Epileptic seizures and syndromes*. London: John Libbey & Company Ltd, 1994: 213–220
39. JANZ D. Epilepsy with grand mal on awakening and sleep-waking cycle. *Clin Neurophysiol* 2000; 111 Suppl 2:S103–S110
40. APPLETON RE, PANAYIOTOPOULOS CP, ACOMB BA et al. Eyelid myoclonia with typical absences: an epilepsy syndrome. *J Neurol Neurosurg Psychiatr* 1993; 56:1312–1316
41. GIANNAKODIMOS S, PANAYIOTOPOULOS CP. Eyelid myoclonia with absences in adults: a clinical and video- EEG study. *Epilepsia* 1996; 37:36–44
42. PANAYIOTOPOULOS CP, FERRIE CD, GIANNAKODIMOS S et al. Perioral myoclonia with absences: a new syndrome. In: Wolf P, ed. *Epileptic seizures and syndromes*. London: John Libbey & Company Ltd, 1994: 143–153
43. BILGIC B, BAYKAN B, GURSES C et al. Perioral myoclonia with absence seizures: a rare epileptic syndrome. *Epileptic Disord* 2001; 3:23–27
44. PANAYIOTOPOULOS CP. *A clinical guide to epileptic syndromes and their treatment*. Oxford: Bladon Medical Publishing, 2002
45. BANCAUD J, TALAIRACH J. Clinical semiology of frontal lobe seizures. *Adv Neurol* 1992; 57:3–58
46. RAYMOND AA, FISH DR, SISODIYA SM et al. Abnormalities of gyration, heterotopias, tuberous sclerosis, focal cortical dysplasia, microdysgenesis, dysembryoplastic neuroepithelial tumour and dysgenesis of the archicortex in epilepsy. Clinical, EEG and neuroimaging features in 100 adult patients. *Brain* 1995; 118:629–660
47. FERRIE CD, GIANNAKODIMOS S, ROBINSON RO et al. Symptomatic typical absence seizures. In: Duncan JS, Panayiotopoulos CP, eds. *Typical absences and related epileptic syndromes*. London: Churchill Communications Europe, 1995: 241–252
48. NORTH KN, OUVRIER RA, NUGENT M. Pseudoseizures caused by hyperventilation resembling absence epilepsy. *J Child Neurol* 1990; 5:288–294
49. COVANIS A, SKIADAS K, LOLI N et al. Absence epilepsy: early prognostic signs. *Seizure* 1992; 1:281–289
50. WIRRELL E, CAMFIELD C, CAMFIELD P et al. Prognostic significance of failure of the initial antiepileptic drug in children with absence epilepsy. *Epilepsia* 2001; 42:760–763
51. APPLETON RE, BEIRNE M. Absence epilepsy in children: the role of EEG in monitoring response to treatment. *Seizure* 1996; 5:147–148
52. DUNCAN JS. Antiepileptic drugs and the electroencephalogram. *Epilepsia* 1987; 28:259–266
53. VILLARREAL HJ, WILDER BJ, WILLMORE LJ et al. Effect of valproic acid on spike and wave discharges in patients with absence seizures. *Neurology* 1978; 28:886–891
54. DAVIS R, PETERS DH, MCTAVISH D. Valproic acid. A reappraisal of its pharmacological properties and clinical efficacy in epilepsy. [Review] [270 refs]. *Drugs* 1994; 47:332–372
55. BERKOVIC SF, ANDERMANN F, GUBERMAN A et al. Valproate prevents the recurrence of absence status [see comments]. *Neurology* 1989; 39:1294–1297
56. VERROTTI A, GRECO R, CHIARELLI F et al. Epilepsy with myoclonic absences with early onset: a follow-up study. *J Child Neurol* 1999; 14:746–749

57. ACHARYA S, BUSSEL JB. Hematologic toxicity of sodium valproate. *J Pediatr Hematol Oncol* 2000; 22:62–65
58. BRYANT AE, III, DREIFUSS FE. Valproic acid hepatic fatalities. III. U.S. experience since 1986 [see comments]. *Neurology* 1996; 46:465–469
59. CRAWFORD P, APPLETON R, BETTS T et al. Best practice guidelines for the management of women with epilepsy. The Women with Epilepsy Guidelines Development Group. *Seizure* 1999; 8:201–217
60. LAEGREID L, KYLLERMAN M, HEDNER T et al. Benzodiazepine amplification of valproate teratogenic effects in children of mothers with absence epilepsy. *Neuropediatrics* 1993; 24:88–92
61. CHAPPELL KA, MARKOWITZ JS, JACKSON CW. Is valproate pharmacotherapy associated with polycystic ovaries? *Ann Pharmacother* 1999; 33:1211–1216
62. GENTON P, BAUER J, DUNCAN S et al. On the association between valproate and polycystic ovary syndrome. *Epilepsia* 2001; 42:295–304
63. HERZOG AG, SCHACHTER SC. Valproate and polycystic ovarian syndrome: Final thoughts. *Epilepsia* 2001; 42:311–315
64. LERMAN-SAGIE T, WATEMBERG N, KRAMER U et al. Absence seizures aggravated by valproic acid. *Epilepsia* 2001; 42:941–943
65. SATO S, WHITE BG, PENRY JK et al. Valproic acid versus ethosuximide in the treatment of absence seizures. *Neurology* 1982; 32:157–163
66. GERICKE CA, PICARD F, SAINT-MARTIN A et al. Efficacy of lamotrigine in idiopathic generalized epilepsy syndromes: a video-EEG-controlled, open study. *Epileptic Disord* 1999; 1:159–165
67. CULY CR, GOA KL. Lamotrigine. A review of its use in childhood epilepsy [In Process Citation]. *Paediatr Drugs* 2000; 2:299–330
68. BIRABEN A, ALLAIN H, SCARABIN JM et al. Exacerbation of juvenile myoclonic epilepsy with lamotrigine. *Neurology* 2000; 55:1758
69. GUBERMAN AH, BESAG FM, BRODIE MJ et al. Lamotrigine-associated rash: risk/benefit considerations in adults and children. *Epilepsia* 1999; 40:985–991
70. PANAYIOTOPOULOS CP, FERRIE CD, KNOTT C et al. Interaction of lamotrigine with sodium valproate [letter] [see comments]. *Lancet* 1993; 341:445
71. ECHANIZ-LAGUNA A, THIRIAUX A, RUOLT-OLIVESI I et al. Lupus anticoagulant induced by the combination of valproate and lamotrigine. *Epilepsia* 1999; 40:1661–1663
72. MATTSON RH, CRAMER JA. Valproic acid and ethosuximide interaction. *Ann Neurol* 1980; 7:583–584
73. MIKKELSEN B, BIRKET-SMITH E, BRADT S et al. Clonazepam in the treatment of epilepsy. A controlled clinical trial in simple absences, bilateral massive epileptic myoclonus, and atonic seizures. *Arch Neurol* 1976; 33:322–325
74. OBEID T, PANAYIOTOPOULOS CP. Clonazepam in juvenile myoclonic epilepsy. *Epilepsia* 1989; 30:603–606
75. AMES FR, ENDERSTEIN O. Clinical and EEG response to clonazepam in four patients with self-induced photosensitive epilepsy. *S Afr Med J* 1976; 50:1432–1434
76. BROWNE TR. Clonazepam. *N Engl J Med* 1978; 299:812–816
77. LOMBROSO CT, FORSYTHE I. Long term follow-up of acetazolamide (diamox) in the treatment of epilepsy. *Epilepsia* 1969; 1:493–500
78. RESOR SR Jr, RESOR LD. Chronic acetazolamide monotherapy in the treatment of juvenile myoclonic epilepsy [see comments]. *Neurology* 1990; 40:1677–1681
79. DI BONAVENTURA C, FATTOUCH J, MARI F et al. Clinical experience with levetiracetam in idiopathic generalised epilepsy according to different syndrome subtypes. *Epileptic Disord* 2005; 7:231–235
80. BERKOVIC SF, KNOWLTON RC, LEROY RF et al. Placebo-controlled study of levetiracetam in idiopathic generalised epilepsy. *Neurology* 2007; 69:1752–1760
81. SNEAD OC, HOSEY LC. Exacerbation of seizures in children by carbamazepine. *New Engl J Med* 1985; 313:916–921
82. PARKER AP, AGATHONIKOU A, ROBINSON RO et al. Inappropriate use of carbamazepine and vigabatrin in typical absence seizures. *Dev Med Child Neurol* 1998; 40:517–519
83. SCHAPPEL G, CHADWICK D. Tiagabine and non-convulsive status epilepticus. *Seizure* 1996; 5:153–156
84. GENTON P. When antiepileptic drugs aggravate epilepsy. *Brain Dev* 2000; 22:75–80
85. KNAKE S, HAMER HM, SCHOMBURG U et al. Tiagabine-induced absence status in idiopathic generalized epilepsy. *Seizure* 1999; 8:314–317
86. OSORIO I, REED RC, PELTZER JN. Refractory idiopathic absence status epilepticus: A probable paradoxical effect of phenytoin and carbamazepine. *Epilepsia* 2000; 41:887–894
87. D'AGOSTINO MD, ANDERMANN F, DUBEAU F et al. Exceptionally long absence status: multifactorial etiology, drug interactions and complications. *Epileptic Disord* 1999; 1:229–232