

Presurgical evaluation and outcome of epilepsy surgery in childhood

J. HELEN CROSS

UCL Institute of Child Health, Great Ormond Street Hospital for Children NHS Trust,
London and National Centre for Young People with Epilepsy, Lingfield

Introduction

Surgery in the management of children with epilepsy is not new. Murray Falconer, a neurosurgeon at the Maudsley Hospital, recognised that children as well as adults may benefit from resective surgery, but the age range of his patients did not include the very young¹. Traditionally, focal seizures have been more difficult to diagnose in the young child, both clinically and electrographically, and a focal onset to seizures may not be readily apparent. However, the advent of magnetic resonance imaging (MRI), with the increased detection of structural focal brain abnormality, has opened up the possibility of surgery at an earlier stage in the natural history of childhood epilepsy.

Selection criteria

There are several points to discuss when considering whether surgery may be more beneficial earlier rather than later. Many adults presenting for resective surgery have a history of seizures arising from early childhood, and have been through multiple antiepileptic drugs (AEDs). Prior to the recognition of different types of epilepsy there was concern that children may 'grow out' of epilepsy but with the use of the classification of the epilepsies the benign syndromes can now be recognised at an early stage, and when these have been excluded the focal epilepsies are among the most drug resistant. Chronic epilepsy is not without psychosocial morbidity however; the Oxford study of 100 children with temporal lobe epilepsy demonstrated that at least one-third were not leading an independent life in adulthood². Early surgery may therefore reduce the morbidity associated with frequent seizures through the teenage years.

There are specific issues related to children that need to be considered in the discussion of the early surgical treatment of epilepsy. The definition of 'medically intractable epilepsy' in adult practice is often defined as epilepsy which has not responded to at least three AEDs over at least a three-year period. Although in the older child attending normal school this may have relevance, in the young child experiencing recurrent seizures, and where compromise to developmental progress has been demonstrated, it is likely that a greater number of drugs will have been tried over a lesser period of time. Perhaps the most appropriate definition of intractability in children is 'inadequate seizure control in spite of appropriate medical therapy' with no particular timescale. This has been addressed in the recent ILAE report on drug resistance, where drug-resistant epilepsy is now defined as 'a failure of adequate trials of two tolerated and appropriately chosen and used AED schedules, whether as monotherapies or in combination, to achieve sustained seizure freedom'³.

The whole issue of what is ‘intractability’ in childhood remains a question for debate, and we lack tools for prediction of prognosis. We know from epidemiological studies that poor prognostic indicators are early onset of seizures, poor response to first-line medication, focal seizures, and a demonstrable structural lesion. We can therefore only assume that with early cessation of seizures, we allow the child to achieve its optimal learning potential. Longitudinal studies post surgery are lacking, not least because of a lack of standardised tools to assess cognitive performance across all ages. However, at the very least, children have been demonstrated to maintain their developmental trajectory post surgery, that would otherwise have been lost, and recent data looking at children who have undergone early surgery suggests improved developmental outcome may be achieved⁴. More recent data suggest greater benefits may be achieved in the longer term, with studies demonstrating greater developmental gains in seizure-free patients the longer time passes after surgery^{5,6}.

The group of children for whom surgery is considered is also more diverse than the adult group. A significant number will have developmental compromise, in whom an improved quality of life is a priority rather than solely freedom from seizures (although this is obviously a consideration). Assessment for surgery should be in the context of a complex epilepsy service⁷.

Types of surgery

The types of surgery performed in children do not differ a great deal from those in adults, but the proportion of each procedure carried out, and the type of patient on which it is performed, both vary. A recent international survey of 458 operations performed in 450 children over a 12-month period (2004) revealed two-thirds (63%) to be hemispherectomy or multilobar resections (Fig. 1). Unilobar resections or lesionectomies were undertaken in 30%, with only a very small number of functional procedures being performed⁸. Furthermore, 63% were due to underlying developmental as opposed to acquired pathology⁸.

Focal resection involves removal of a small part or the whole of one lobe. Seizures should be shown to arise from one area of the brain, the removal of which will not interfere significantly with function. Hemispherectomy is considered in children with a pre-existent hemiparesis (in the absence of progressive disease) with a demonstrable structural abnormality of the contralateral hemisphere. In a small number of children with Rasmussen’s syndrome (chronic encephalitis involving one cerebral hemisphere) surgery may be considered prior to the development of a dense hemiparesis. This may also be considered in children with Sturge-Weber syndrome with early onset seizures.

Corpus callosotomy is considered in children with ‘drop’ attacks, whatever the seizure type (e.g. akinetic, myoclonic, tonic). This procedure is unlikely to have any effect on other seizure types, and a child is highly unlikely to be rendered seizure free by the procedure. Subpial transection may be considered for children with acquired epileptic aphasia (Landau-Kleffner syndrome). The procedure involves transection of transverse fibres, theoretically leaving vertical functional tracts intact. In Landau-Kleffner syndrome the technique is performed over Wernicke’s area of the driving hemisphere (determined by presurgical investigation) under electrocorticographic guidance. The theory of preservation of vertical fibres allows the technique also to be used in children where the seizure focus lies within functionally eloquent cortex but is unlikely to lead to benefit in the absence of a concomitant focal resection. Data on outcome and relative benefits of this procedure compared to medical treatment are limited.

Figure 1A

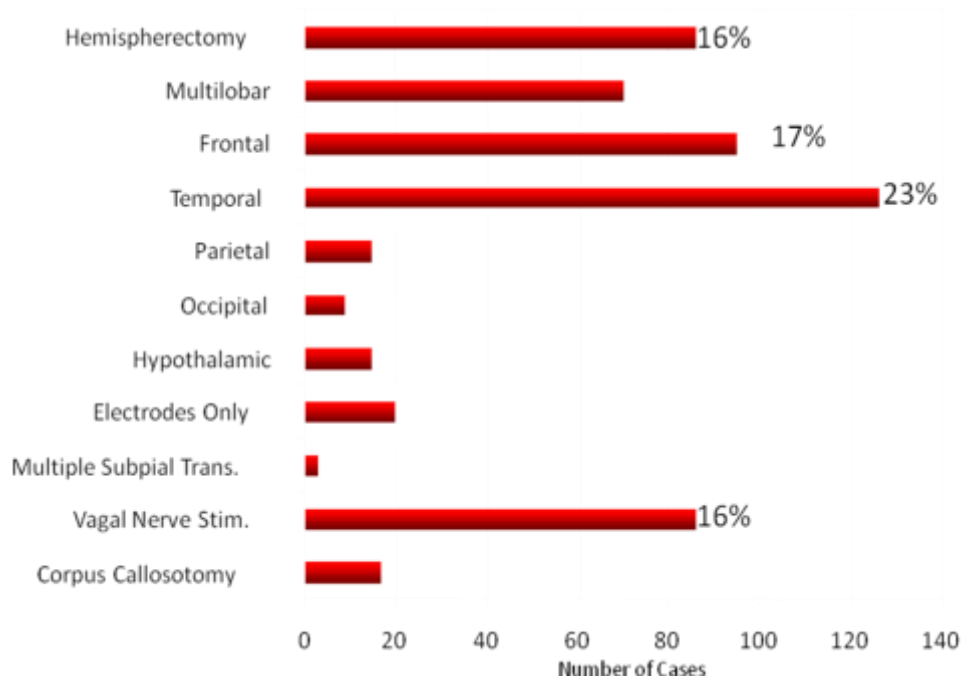


Figure 1B

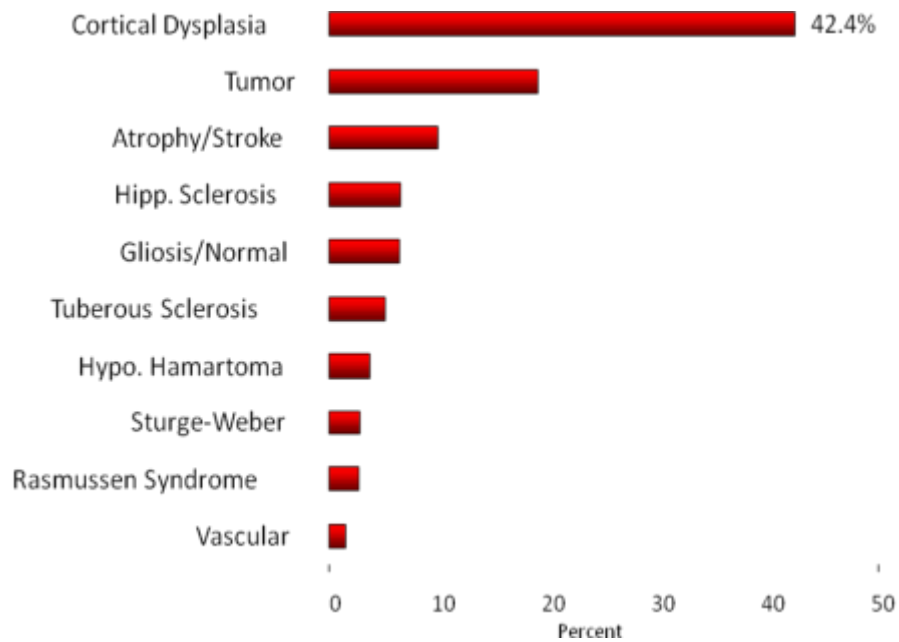


Figure 1. Relative proportions of procedures (A) and pathology (B) in the 2004 ILAE survey of surgical operations in children for epilepsy.

The presurgical evaluation

In all types of resective epilepsy surgery presurgical evaluation aims to establish the area from which seizures arise, and to determine that removal of that area will not further compromise the child, i.e. the seizure focus to be resected does not lie in functionally critical cortex. In all children this must start with full clinical evaluation, not only to detail full seizure and AED history, but also to determine the degree of any clinical neurological abnormality, and whether the expectations of the family are realistic. It is current practice at Great Ormond Street to use a predominantly non-invasive presurgical work-up, and the following outlines our current investigation protocol. It is important to emphasise that no investigation provides all the information that is required, and a multidisciplinary approach is mandatory.

Focal resection

Optimised MRI (with extensions of this in temporal lobe epilepsy such as T2 relaxometry of the hippocampi, volumetrics), including a 3D data set to determine any evidence of focal brain abnormality. In children aged three months to two years however areas of neocortical abnormality may not be apparent in view of incomplete myelination. This is related to functional abnormality with ictal and inter-ictal EEG, as well as ictal and inter-ictal SPECT in selected cases.

Hemispherectomy

MRI to assess the extent and pathology of the structural abnormality of the abnormal hemisphere, as well as review of the 'normal' side to make sure there is no evidence of more widespread disease. EEG, ictal and inter-ictal, for lateralisation. Bilateral inter-ictal EEG abnormalities do not preclude consideration for surgery^{9,10}.

Functional procedures

Corpus callosotomy. Clinical history is the main assessment tool, not only to determine seizure type and frequency but to determine social goals. MRI and EEG to determine no evidence of focal disease.

Subpial transection. The investigation of children with Landau-Kleffner syndrome is specific to determining which side may be responsible, and therefore whether surgery can be considered. MRI is performed to exclude a structural brain abnormality. EEG in various forms of sophistication (awake, sleep, possibly ictal, under methohexitone suppression, along with magnetoencephalography) provides the majority of information required.

The role of neuropsychology

Since early pathologies often result in reorganisation of function, the major goal of neuropsychological evaluation is to determine lateralisation and focal representation of function. As in adults, cognitive evaluation predominantly involves assessment of core functions such as intelligence, memory, language, reading and writing. The sodium amylobarbitone (amytal) or WADA procedure has a useful role in determining abnormal language representation in adults who may have suffered congenital or early insult to the left hemisphere. It can also be used to assess memory function prior to surgery, to reduce the risk of an amnesic syndrome. However developments in functional MRI, assessed in combination with full neuropsychology assessment in experienced hands, mean that the WADA test is now rarely performed for assessment of language in children, particularly for temporal resection.

The role of invasive monitoring

Despite the improved techniques in non-invasive presurgical evaluation, there remains a small proportion of children who benefit from invasive EEG monitoring. whether with subdural grids with or without depth electrodes or in some centres stereo EEG. These are children in whom there is concern that the seizure focus lies within a functionally eloquent area, in children with extratemporal epilepsy in whom all data are concordant but there is no structural abnormality on MRI, and those in whom data are suggestive of a single focus but there may be some doubt.

The role of neuropsychiatry

The exact aims of surgery require discussion to review whether expectations on the part of the patient and family are realistic. This has particular relevance in childhood, as the group under consideration is clinically heterogeneous, and outcome aims are diverse. In particular, in a young child with severe developmental delay and extremely frequent seizures, the aims of surgery may be more related to improved developmental progress and quality of life with of course a reduction of seizures. An older child in normal school is more likely to be seeking seizure freedom and a greater independence. Other associated issues must also be addressed, such as behaviour and any realistic appreciation of change that is unlikely to be predictable. A contract between the professionals and family is desirable prior to the surgical decision.

Table II. Seizure-free outcome according to procedure and pathology.

	Wyllie et al 1998 ¹² <i>F/up 1–7.4 years</i>	Mathern et al 1999 ¹³ <i>F/up 6m–10 years</i>	GOSH ¹⁴ <i>F/up > 2 year</i>
Hemispherectomy	11/16 (69%)	40/62 (64%)	16/28 (57%)
- Cortical dysplasia		18/26 (69%)	5/15 (33%) ⁸ (HME 20%, other 50%)
- Other		22/36 (61%)	11/13 (82%)
Temporal resection	14/21 (67%)	13/20 (65%)	34/59 (58%)
- Hippocampal sclerosis	5/9 (56%)	7/8 (87%)	16/30 (53%)
- Cortical dysplasia		}6/12 (50%)	}18/26 (69%)
- Tumour	24/28 (86%)	}	}
Extratemporal/ multilobar resection			
- Cortical dysplasia	11/22 (50%)	16/29 (55%)	22/37 (59.5%)
- Tumour	12/16 (75%)	0	15/22 (68.2%)
- Other		5/13 (38%)	

GOSH: Great Ormond Street Hospital

Outcome

Outcome of epilepsy surgery should be measured not only in terms of seizure freedom, but also in terms of development, neuropsychology, behaviour and quality of life⁶. Seizure freedom is quoted most often in outcome studies no doubt as it is the easiest to determine. Large post-surgical series have shown seizure freedom in 40–87%¹²⁻¹⁴ (Table II) related more to the underlying pathology than age at onset of seizures, age at surgery, duration of epilepsy or procedure performed, with better outcome seen with acquired as opposed to developmental pathology.

With focal resection, the degree of epileptogenic tissue removed is a major determinant of seizure outcome, although the degree to which this can be achieved is also related to the underlying pathology. There is some evidence that the outcome following surgery for developmental lesions may deteriorate with time, that is the likelihood of seizure freedom is less in the longer as opposed to the short term, but that outcome with such lesions may be better with earlier surgery⁸. The lesser likelihood of seizure control however does not preclude consideration, providing the aims of surgery are realistic and clearly identified preoperatively. Many children are also likely to achieve a substantial reduction in seizure frequency⁹⁻¹¹ with a reduction in anticonvulsant requirement.

Developmental outcome has been reported as improved following surgery in many studies but has been difficult to quantify, particularly in the very young, as outlined above. As a consequence it is important to obtain as much information as possible about the nature of the epilepsy and the procedure planned, with clear outcome aims clarified with the family.

It is for this reason that a system of categorisation of epilepsy surgery on the basis of the probability of success has been proposed⁶. This would divide between those in which techniques and prognosis are well established (e.g. conventional temporal lobectomy and hemispherectomy for acquired lesions), those in which prognosis is not so clear-cut (e.g. extratemporal resections, hemispherectomy for developmental lesions, certain temporal lobectomies), and procedures performed on highly problematic individuals in whom surgical intervention may help (e.g. callosal section, subpial transection, trials of partial resection of abnormal tissue).

References

1. DAVIDSON, S. and FALCONER, M.A. (1975) Outcome of surgery in 40 children with temporal lobe epilepsy. *Lancet* *i*, 1260-1263.
2. OUNSTED, C., LINDSAY, J. and RICHARDS, P. (1995) *Temporal Lobe Epilepsy 1948–1986. A Biographical Study*. Macekith Press, Oxford.
3. KWAN, P., ARZIMANOGLU, A., BERG, A. et al (2010) Definition of drug resistant epilepsy: consensus proposal by the ad hoc Task Force of the ILAE Commission on Therapeutic Strategies *Epilepsia* *51*, 1069-1077
4. LODDENKEMPER, T., HOLLAND, K.D., STANFORD, L.D. et al (2007) Developmental outcome after epilepsy surgery in infancy *Pediatrics* *119*, 930-935.
5. FREITAG, H., TUXHORN, I. (2005) Cognitive function in preschool children after epilepsy surgery: rationale for early intervention. *Epilepsia* *46*, 561-7.
6. SKIRROW, C., CROSS, J.H., CORMACK F. et al (2011) Long-term intellectual outcome after temporal lobe surgery in childhood. *Neurology* *12*, 1330-1337.
7. CROSS, J.H., JAYAKAR, P., NORDLI, D. et al (2006), Proposed criteria for referral and evaluation of children with epilepsy for surgery *Epilepsia* *47*, 952-959.
8. HARVEY, A.S., CROSS, J.H., SHINNAR, S., MATHERN, G.W., and the Paediatric Epilepsy Surgery Survey Taskforce (2008) Defining the spectrum of international practice in paediatric epilepsy surgery patients. *Epilepsia* *49*, 46-155.
9. SMITH, S.J.M., ANDERMANN, F., VILLEMURE, J.-G. et al (1991) Functional hemispherectomy: EEG findings spiking from isolated brain postoperatively and prediction of outcome. *Neurology* *41*, 1790-1794.
10. DORING, S., CROSS, H., BOYD, S. et al (1999) The significance of bilateral abnormalities before and after hemispherectomy in children with unilateral major hemisphere lesions. *Epilepsy Res* *34*, 65-73.

11. TAYLOR, D.C., NEVILLE, B.G.R. and CROSS, J.H. (1997) New measures of outcome of the surgical treatment of epilepsy. *Epilepsia* 38, 625-630.
12. WYLLIE, E., COMAIR, Y., KOTAGAL, P. et al (1998) Seizure outcome after epilepsy surgery in children and adolescents. *Ann Neurol* 44, 740-748.
13. MATHERN, G.W., GIZA, C.C., YUDOVIN, S. et al (1999) Postoperative seizure control and antiepileptic drug use in pediatric epilepsy surgery patients: the UCLA experience, 1976–1997. *Epilepsia* 40, 1740-1749.
14. DEVLIN, A.M., CROSS, J.H., HARKNESS, W. et al (2003) Clinical outcomes of hemispherectomy for epilepsy in childhood and adolescence. *Brain* 126, 556-566.

Further reading

ENGEL, J. Jr. (1993) *Surgical Treatment of the Epilepsies*, 2nd Edition. Raven Press, New York.